









Uterine Artery Embolization as an Effective Management and Diagnostic Tool for Puerperal Uterine Inversion with Severe Postpartum Bleeding: A Case Report

자궁내번증으로 인한 중증 산후 출혈 환자에서 효율적인 조치 및 진단적 도구로서의 자궁동맥색전술: 증례 보고

Seong Ju Kim, MD¹ , Youngjong Cho, MD^{1*} , Sung-Joon Park, MD² , Sangjoon Lee, MD³ , Hyoung Nam Lee, MD⁴ , Da Hye Ju, MD⁵ 

Departments of ¹Radiology and ⁵Obstetrics and Gynecology, GangNeung Asan Hospital, Gangneung, Korea

²Department of Radiology, Korea University Ansan Hospital, Ansan, Korea

³Department of Radiology, Pohang St. Mary's Hospital, Pohang, Korea

⁴Department of Radiology, Soonchunhyang University College of Medicine, Cheonan Hospital, Cheonan, Korea

Acute puerperal uterine inversion is a rare postpartum obstetric complication; however, without rapid diagnosis and appropriate management, it is life-threatening. Substantial bleeding hinders the verification of a partially inverted uterus, possibly delaying the treatment. Herein, we present the report of a 32-year-old female presenting with massive postpartum bleeding managed by uterine artery embolization. The peculiar course of the uterine artery bowing inferiorly along the inverted fundus during embolization could uncover the uterine inversion, which was not diagnosed by physical examination and CT. In conclusion, uterine artery embolization is not only an effective therapeutic strategy for postpartum hemorrhage but also a valuable tool for diagnosing uterine inversion.

Index terms Uterine Inversion; Postpartum Hemorrhage; Uterine Artery Embolization

INTRODUCTION

Uterine inversion is a rare postpartum complication in which the uterine fundus par-

Received April 11, 2021

Revised July 3, 2021

Accepted July 26, 2021

*Corresponding author

Youngjong Cho, MD
Department of Radiology,
GangNeung Asan Hospital,
38 Bangdong-gil, Sacheon-myeon,
Gangneung 25440, Korea.

Tel 82-33-610-3489

Fax 82-33-610-3490s


E-mail ohggamja@naver.com

This is an Open Access article distributed under the terms of the Creative Commons Attribution Non-Commercial License (<https://creativecommons.org/licenses/by-nc/4.0>) which permits unrestricted non-commercial use, distribution, and reproduction in any medium, provided the original work is properly cited.


ORCID iDs

Seong Ju Kim 


<https://orcid.org/0000-0002-0677-4627>

Youngjong Cho 


<https://orcid.org/0000-0003-2881-9221>

Sung-Joon Park 


<https://orcid.org/0000-0002-1187-7671>

Sangjoon Lee 

<https://orcid.org/0000-0001-6492-514X>

Hyoung Nam Lee 

<https://orcid.org/0000-0002-2135-9384>

Da Hye Ju 

<https://orcid.org/0000-0003-4246-2193>

tially or completely collapses into the endometrial cavity (1). It is a life-threatening complication, requiring rapid diagnosis and immediate treatment. Typically, uterine inversion is diagnosed based on clinical symptoms observed during physical examination (2). Patients often present with abdominopelvic pain and hypovolemic shock due to severe postpartum bleeding. Bimanual examinations may reveal a smooth round mass protruding from the cervix or vagina. However, massive bleeding during examinations hinders its detection, even when using US, CT, or MRI. Herein, we have presented a case of acute puerperal uterine inversion with severe bleeding referred for uterine artery embolization, which was initially misdiagnosed as uterine rupture based on physical examination and CT findings.

CASE REPORT

A 32-year-old primigravida postpartum patient with unremarkable medical history was transferred to our emergency center with massive hemorrhage. She delivered a baby 1.5 hours ago via normal vaginal delivery at a local clinic. Her vital signs (blood pressure: 92/63 mm Hg and pulse rate: 132 bpm) were unstable. The uterine fundus was not palpated during physical examination and multiple active bleeding foci with abundant hematomas were observed through the speculum. Abdominopelvic CT angiography, which was performed to identify the cause of bleeding, revealed an abnormally shaped uterus with fundus bulging into the vaginal cavity. However, during emergency assessment, the abdominal radiologist did not suspect uterine inversion. Based on physical examination, CT findings, and the radiologist's assessment of partial loss of myometrial enhancement due to uterine rupture and myometrial injury (Fig. 1A, B), uterine rupture was suspected preferentially. Uterine arterial embolization was recommended to stabilize the patient's vital signs before surgical correction.

Under local anesthesia and direct US guidance, the right common femoral artery was accessed with a micropuncture kit (Micro-stick, Medcomp, Harleyville, PA, USA). When an adequate pulsatile arterial flow was detected, a 0.035-inch guidewire was advanced and a 5-Fr vascular sheath (Radiofocus, Terumo, Shibuya, Tokyo, Japan) was placed through the guidewire. A 5-Fr angiographic catheter (Cobra-2, Cook, Bloomington, IN, USA) was used for the selective angiography of contralateral internal iliac artery. During the procedure, an engorged tortuous uterine artery with an unexpected course was identified. The ascending portion bowed inferiorly along the course of uterine fundus (Fig. 1D, E), and the other side of the artery had a similar feature on selective angiogram (not shown). These findings suggested uterine inversion. After discussion with the obstetric surgeon, uterine artery embolization with gelatin microparticles was performed (150–350 μm , EGgel, Hwaseong, Korea) for hemostasis before surgical correction. Her blood pressure subsequently normalized and she was transferred to operating room, where uterine inversion was confirmed and bimanual reduction was performed. The patient was discharged after 10 days. A 2-month follow-up US revealed a normal uterus with pre-existing intramural-type myoma (Fig. 1F).

This study obtained an Institutional Review Board approval from the institution, and the need for informed consent was waived (IRB No. 2020-12-006).

Fig. 1. A 32-year-old female with postpartum hemorrhage.

A. Abdominopelvic angiographic CT scan (venous phase) shows the margin of the uterus is not clearly demarcated. In addition, the myometrial enhancement is partially absent and contains many hematomas (arrowheads). These findings were initially recognized as uterine rupture.

B. Coronal reformatted abdominopelvic angiographic CT scan (venous phase) shows the top of the uterus configuration is cleaved (arrowheads) with the fundus inverted into the uterine cavity. Note the low-attenuated round lesion (arrow) inside the myometrium wall, suggesting intramural-type uterine myoma as a possible predisposing factor for uterine inversion.

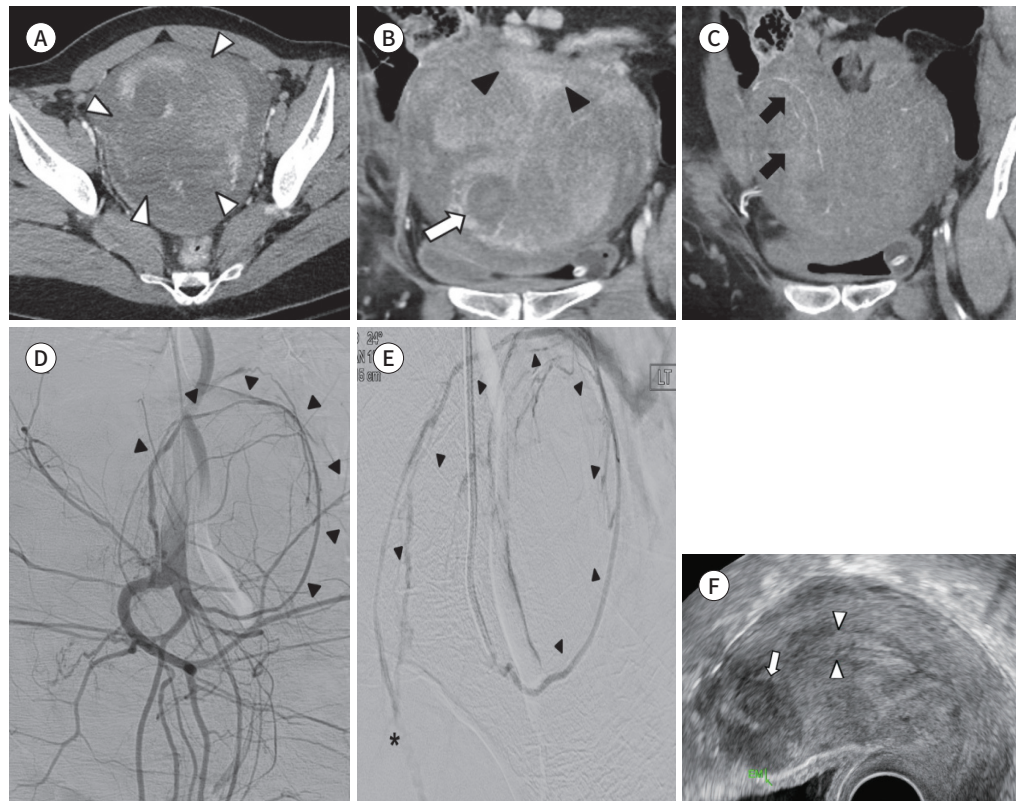
C. Coronal reformatted abdominopelvic angiographic CT scan (arterial phase) shows the uterine artery is extended and penetrates the uterus from the fundus to the cervix; this is known as the thread and streak sign (arrows).

D. Digital subtraction angiographic image (RAO 28°) shows the left uterine artery arising from the anterior division of the left internal iliac artery (arrowheads).

E. Digital subtraction angiographic image (RAO 24°) shows the left uterine artery is selectively catheterized. The uterine artery runs upward and then bows inferiorly (arrowheads). The unexpected course of the uterine artery may imply uterine inversion. Note that ovarian collaterals are visualized at the end of the uterine artery (asterisk).

F. Transvaginal US image of the uterus shows the normal uterine configuration with normal endometrium (arrowheads) and pre-existing intramural-type myoma (arrow) at the 2-month follow-up.

RAO = right anterior oblique



DISCUSSION

The incidence of uterine inversion is 2.9 per 10000 deliveries (1). This life-threatening postpartum complication may be accompanied by severe hemorrhage. In uterine inversion, the myometrium is unable to contract and retract that resulting in severe blood loss (3). Furthermore, when the broad ligament and peritoneal nerves are stretched by uterine inversion, para-

sympathetic tone is increased that leading to shock condition (2). Therefore, Rapid diagnosis and management are crucial to prevent maternal deaths and obtain favorable prognosis.

Uterine inversion is classified by time of occurrence or degree of inversion. Inversion is acute (< 24 hours after delivery), subacute (> 24 hours but \leq 4 weeks), or chronic (> 4 weeks) (4). The severity of inversion depends on fundus extension. In first-degree inversion, the fundus remains within the endometrial cavity. Second-degree uterine inversion occurs when the fundus reaches the cervical external os without exceeding the perineum. In third-degree inversion, the fundus extends over the perineum, and in fourth-degree inversion, both the uterus and vagina completely prolapse outside the vulva (2). In our patient, inversion occurred immediately postpartum and the fundus was located around the cervical ring, suggesting second-degree acute uterine inversion.

Predisposing factors include nulliparity, macrosomia, rapid or prolonged labor and delivery, short umbilical cord, severe preeclampsia, use of uterine relaxants, uterine anomalies or tumors (leiomyoma), retained placenta, and placenta accrete (5). Nulliparity and three leiomyomas were risk factors in our patient.

Early diagnosis of the uterine inversion depends on clinical manifestations. Palpation of a congested bleeding mass protruding from the cervix or vagina provides confirmation. However, examinations during massive bleeding are difficult. Furthermore, first- or second-degree inversions may be misdiagnosed as prolapsed fibroid (unlike third- and fourth-grade inversions) (6). US, CT, and MRI are helpful when the diagnosis is uncertain. The US central cleavage sign typically indicates uterine inversion (7). However, our patient was misdiagnosed with uterine rupture after US owing to misinterpretation of the fundus protruding into the pelvic cavity.

Our patient's hemodynamic status was unstable; therefore, we performed CT angiography, although MRI is effective for confirmation of uterine inversion and delineation from surrounding structure (2). A previous report identified a unique CT angiographic feature—the thread and streak sign—where the uterine arteries stretch and penetrate the uterine cavity (7). We detected this feature in retrospective CT review (Fig. 1C). Nevertheless, the radiologist misdiagnosed the patient with uterine rupture (consistent with US findings) due to unclear uterine margin and partially absent myometrium enhancement.

We diagnosed uterine inversion based on the peculiar course of uterine arteries during digital subtraction angiography. Uterine arteries usually ascend along the uterine arteries ascend alongside the uterus to the top; however, in this case both uterine arteries bowed inferiorly along the course of the inverted fundus (Fig. 1D, E). Identification of uterine inversion during transcatheter embolization enabled rapid transfer to the operating room for curative treatment.

Immediate surgery might have been considered a better option than embolization if uterine inversion was clinically suspected. However, surgery can be risky in hemodynamically unstable patients. Furthermore, embolization is a safe and effective treatment for postpartum hemorrhage patients (8-10). Therefore, it was the best option for our patient, even considering a correct clinical diagnosis.

Our patient recovered after uterine artery embolization and bimanual reduction. Postoperative CT revealed uterine focal low attenuation lesions, suggesting mild ischemia (not shown).

However, the 2-month follow-up US revealed a restored uterus with normal endometrium figuration and pre-existing intramural leiomyoma (Fig. 1F).

In conclusion, although manual reduction or surgical techniques such as laparotomy provide definitive uterine inversion treatment, embolization facilitates immediate management of life-threatening situations, including hypovolemic shock. Uterine artery embolization can be a valuable tool for diagnosing uterine inversion reliably.

Author Contributions

Conceptualization, C.Y., J.D.H.; data curation, K.S.J.; formal analysis, all authors; investigation, K.S.J.; methodology, C.Y.; project administration, C.Y.; resources, J.D.H.; supervision, C.Y.; validation, P.S., L.S., L.H.N.; visualization, K.S.J., C.Y.; writing—original draft, K.S.J., C.Y.; and writing—review & editing, P.S., L.S., L.H.N., J.D.H.

Conflicts of Interest

The authors have no potential conflicts of interest to disclose.

Funding

None

REFERENCES

1. Coad SL, Dahlgren LS, Hutcheon JA. Risks and consequences of puerperal uterine inversion in the United States, 2004 through 2013. *Am J Obstet Gynecol* 2017;217:377.e1-377.e6
2. Wendel MP, Shnaekel KL, Magann EF. Uterine inversion: a review of a life-threatening obstetrical emergency. *Obstet Gynecol Surv* 2018;73:411-417
3. Ignacio EA, Osman M, Igboagi U, Razjouyan F, Liddel RP, Hill MC. *Chapter 44 - management of the high-risk obstetric patient*. In Mauro MA, Murphy KP, Thomson KR, Venbrux AC, Morgan RA, eds. *Image-guided interventions*. 3rd ed. Boston: Elsevier 2020:358-363
4. Livingston SL, Booker C, Kramer P, Dodson WC. Chronic uterine inversion at 14 weeks postpartum. *Obstet Gynecol* 2007;109:555-557
5. Wendel PJ, Cox SM. Emergent obstetric management of uterine inversion. *Obstet Gynecol Clin North Am* 1995;22:261-274
6. Momin AA, Saifi SG, Pethani NR, Mitha SH. Sonography of postpartum uterine inversion from acute to chronic stage. *J Clin Ultrasound* 2009;37:53-56
7. Goshima S, Kanematsu M, Kondo H, Watanabe H, Tsuge Y, Furui T, et al. CT angiography of postpartum uterine inversion: intra-uterine thread and streak sign. *European Journal of Radiology Extra* 2009;72:e21-e23
8. Deux JF, Bazot M, Le Blanche AF, Tassart M, Khalil A, Berkane N, et al. Is selective embolization of uterine arteries a safe alternative to hysterectomy in patients with postpartum hemorrhage? *AJR Am J Roentgenol* 2001;177:145-149
9. Lee HY, Shin JH, Kim J, Yoon HK, Ko GY, Won HS, et al. Primary postpartum hemorrhage: outcome of pelvic arterial embolization in 251 patients at a single institution. *Radiology* 2012;264:903-909
10. Pelage JP, Le Dref O, Mateo J, Soyer P, Jacob D, Kardache M, et al. Life-threatening primary postpartum hemorrhage: treatment with emergency selective arterial embolization. *Radiology* 1998;208:359-362

자궁내번증으로 인한 중증 산후 출혈 환자에서 효율적인 조치 및 진단적 도구로서의 자궁동맥색전술: 증례 보고

김승주¹ · 조영중^{1*} · 박성준² · 이상준³ · 이형남⁴ · 주다혜⁵

급성 산후 자궁내번증은 드문 산후합병증의 하나이나 생명을 위협할 수 있어 신속한 진단 및 적절한 치료가 중요하다. 다량의 출혈은 부분 자궁내번증을 진단하는데 어려움을 야기하며 치료를 지연시킬 수 있다. 본 증례는 다량의 산후 출혈을 주소로 온 32세 산모를 자궁동맥색전술을 통해 내번된 자궁의 기저부를 따라서 아래쪽으로 기울어져 주행하는 자궁동맥의 특이적인 주행을 발견하여 자궁내번증으로 빠르게 진단할 수 있었던 증례이다. 이를 통해 자궁동맥색전술은 효율적인 치료를 위한 중재시술뿐만 아니라 자궁내번증의 진단적 도구로 가치가 있음을 보여준다.

강릉아산병원 ¹영상의학과, ⁵산부인과,

²고려대학교 안산병원 영상의학과,

³포항성모병원 영상의학과,

⁴순천향대학교 의과대학 천안병원 영상의학과