

A Morel-Lavallée lesion of the proximal calf in a young trauma patient

A case report

Woo Jong Kim, MD^a, Hong Seop Lee, MD^b, Sung Hun Won, MD^c, Yong Cheol Hong, MD^a, Dhong Won Lee, MD^d, Ji-Hye Lee, MD^e, Chang Hyun Kim, MD^{a,*}

Abstract

Rationale: The Morel-Lavallée lesion (MLL) is a closed degloving injury developing when shear force acts between the muscle fascia and the subcutaneous layer. MLLs develop principally in the trochanteric area or the pelvis; lesions in the proximal calf are rare. Acute lesions can be treated conservatively, but chronic lesions are best treated surgically because of a high rate of recurrence. To the best of our knowledge, this is a rare case of successful treatment of an MLL in the proximal calf associated with tibio-fibular shaft fracture.

Patient concerns: A 14-year-old male visited our emergency room after having been hit by a car. He exhibited direct trauma to the right lower leg and a distal tibio-fibular shaft fracture without an open wound. He underwent surgery to treat the fracture, which was immobilized with splint for 2 weeks post-operatively. At the 3-month follow-up, he complained of a painless, mobile, soft tissue mass in the posteromedial aspect of the proximal calf. Blood circulation was normal and we found no neurological abnormality in the distal region of the lower leg.

Diagnosis: A plain radiograph of the right lower leg revealed a proximal, round, radiopaque soft tissue lesion. Ultrasonography revealed a homogeneous, hypoechoic fluid collection. Magnetic resonance imaging revealed fluid of homogeneous signal intensity between the subcutaneous layer and the underlying fascia of the gastrocnemius muscle.

Interventions: Percutaneous drainage and intralesional steroid injection were performed on several occasions, but the lesion recurred every time. After 5 aspirations, we scheduled surgery. We radically excised the mass and sutured the superficial to the deep fascia to prevent shearing at the surgical plane.

Outcomes: No complication or recurrence was noted at the 1-year follow-up.

Lesson: An MLL in the proximal calf is an uncommon post-traumatic lesion and care must be taken to avoid misdiagnosis. If an MLL is suspected after imaging studies and physical examination, it is important to determine whether the lesion is acute or chronic and to plan treatment accordingly. Appropriate treatment should be given to patients to improve outcomes.

Abbreviations: BMI = body mass index, MLL = Morel-Lavallée lesion, MRI = magnetic resonance imaging, US = ultrasonography.

Keywords: Morel-Lavallée lesion, proximal calf, tibio-fibular shaft fracture

Editor: N/A.

WJK and HSL contributed equally to this study and should be considered co-first authors.

No benefit in any form has been received or will be received from a commercial party related directly or indirectly to the subject of this article.

The authors have no conflicts of interest to disclose.

^a Department of Orthopaedic Surgery, Soonchunhyang University Hospital Cheonan, Dongnam-gu, Cheonan, ^b Department of Foot and Ankle Surgery, Nowon Eulji Medical Center, Eulji University, Nowon-gu, Seoul, ^c Department of Orthopaedic Surgery, Soonchunhyang University Hospital Seoul, Yongsan-gu, Seoul, ^d Department of Orthopaedic Surgery, Konkuk University Medical Center, Gwangjin-gu, Seoul, ^e Department of Pathology, Soonchunhyang University Hospital Cheonan, Dongnam-gu, Cheonan, Korea.

* Correspondence: Chang Hyun Kim, Department of Orthopaedic Surgery, Soonchunhyang University Hospital Cheonan, 31, Suncheonhyang 6-gil, Dongnam-gu, Cheonan 31151, Korea (e-mail: osdrchkim@gmail.com).

Copyright © 2018 the Author(s). Published by Wolters Kluwer Health, Inc. This is an open access article distributed under the terms of the Creative Commons Attribution-Non Commercial License 4.0 (CCBY-NC), where it is permissible to download, share, remix, transform, and buildup the work provided it is properly cited. The work cannot be used commercially without permission from the journal.

Medicine (2018) 97:41(e12761)

Received: 7 June 2018 / Accepted: 18 September 2018

<http://dx.doi.org/10.1097/MD.00000000000012761>

1. Introduction

A Morel-Lavallée lesion (MLL) is a closed degloving injury developing when trauma separates the subcutaneous layer from the muscle fascia. The MLL was first described in 1863 by Maurice Morel-Lavallée; hemolymph collected between the fascial planes after soft tissue injury to the proximal thigh. In 1993, Letournel and Judet described the MLL as an accumulation of blood or plasma after closed degloving of the subcutaneous layer and the muscle fascia of the trochanter in patients with acetabular fractures. The MLL is not common; Tseng and Tornetta et al^[1] reported a 1.7% comorbidity rate in a review of pelvic fracture patients. Effusion may not be extensive in the acute phase and the MLL may be undiagnosed or misdiagnosed as bursitis or simple bruising. However, if the lesion becomes chronic, the recurrence rate is high and complications may develop. Thus, careful initial assessment of trauma patients is essential. MLL develops most frequently in the trochanteric region,^[2] and occasionally in the thigh^[3] and knee,^[4] but rarely in the proximal calf.^[5] Therefore, the risk of misdiagnosis is high; careful examination is required. We present a case of MLL of the proximal calf associated with post-traumatic, tibial shaft fracture in a young patient.

2. Case description

This case report was approved by the Institutional Review Board of Soonchunhyang University Hospital and the patient gave written informed consent for publication of this case report and accompanying images. A 14-year-old male visited our emergency room after being hit by a car. He exhibited direct trauma to the right lower extremity and complained of pain and tenderness in the right calf. We found no wound, no disturbance of blood circulation, and no neurological abnormality. He had no underlying disease or relevant medication history but was obese. On plain radiography, a right, tibio-fibular, distal shaft fracture was evident (Figs. 1A, 1B). The day after admission, he underwent internal fixation using a flexible intra-medullary nail (Titanium Elastic Nail system, Synthes, West Chester, PA) for the tibial fracture and a locking plate (Arix, JEIL Medical Corporation, Seoul, Korea) for the fibular fracture, and was discharged after 2 weeks of long-leg splint immobilization. After discharge, he underwent routine rehabilitation and gradually returned to ambulation during outpatient follow-up. At the 3-month follow-up, he complained of a painless mass on the posteromedial aspect of the proximal calf. Physical examination revealed a mobile swelling but no tenderness (Fig. 2). A plain radiograph of the right lower leg revealed a mildly radio-opaque round lesion in the proximal calf (Fig. 3A); ultrasonography (US) revealed a collection of homogeneous hypoechoic fluid (Fig. 3B). Percutaneous drainage was performed and about 100 mL of serous fluid removed. Two weeks later, the mobile mass had recurred; we performed enhanced magnetic resonance imaging (MRI), which revealed a homogeneous mass of low signal intensity on the T1-weighted image and a high-level signal change

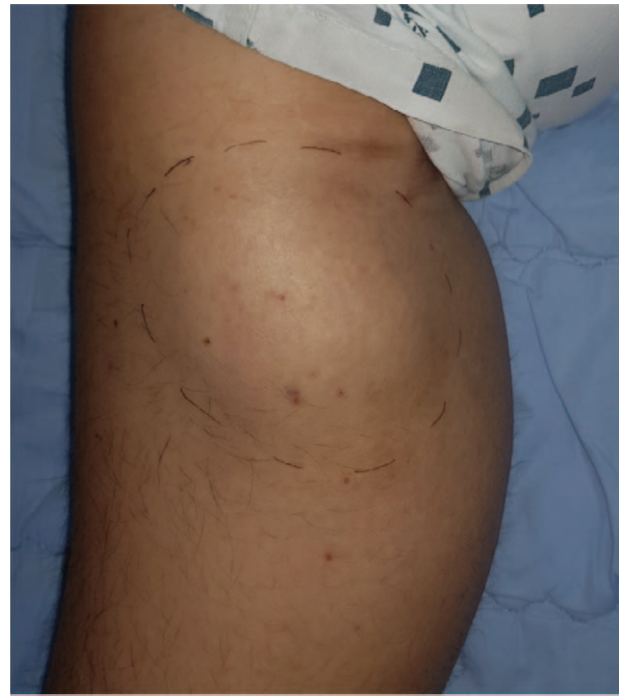


Figure 2. A bulging soft-tissue mass in the posteromedial aspect of the proximal calf.

in the T2-weighted image; the mass was 7.8 cm in the longest diameter (Figs. 4A, 4B). The mass was located in the subcutaneous layer adjacent to the medial head of the

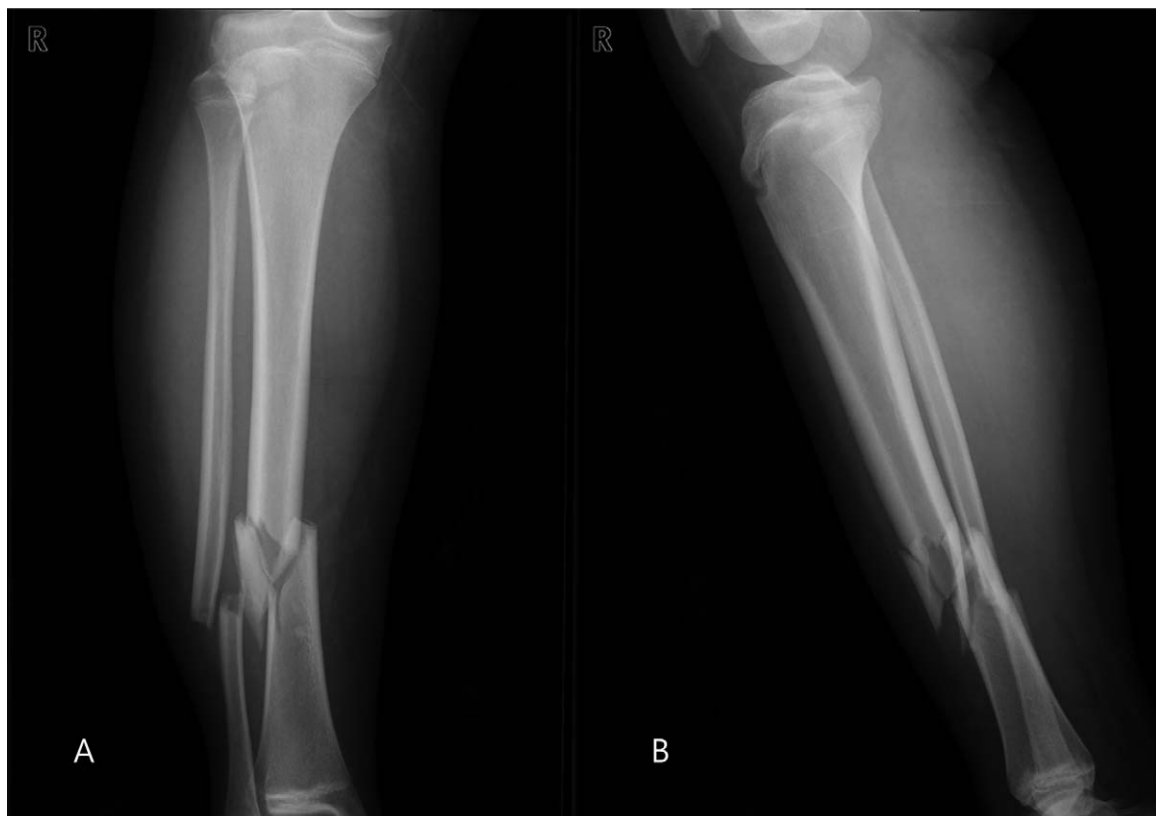

Figure 1. Preoperative plain anteroposterior (A) and lateral (B) radiographic views of the right lower leg showing a fracture of the distal tibio-fibular shaft.

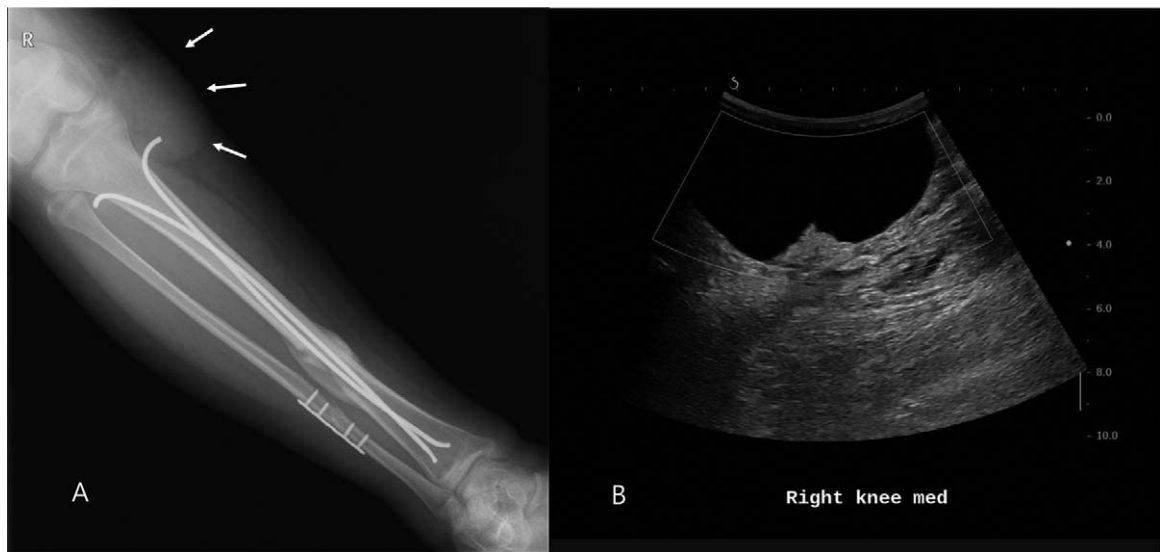


Figure 3. (A) A plain radiograph revealing a subcutaneous round radio-opacity in the proximal calf; and, (B) homogeneous, hypoechoic fluid collection evident on ultrasonography.

gastrocnemius muscle fascia and lacked a connection with the knee joint. We suspected an MLL and decided to continue conservative treatment. During short-term follow-up, fluid collection recurred and we aspirated the fluid 5 times. At 5 months after operation, the fracture site was united, and we decided to remove the internal device and to simultaneously excise the mass, which was located between the subcutaneous tissue and the fascia of the medial gastrocnemius muscle, with some adhesion to the surrounding tissue; the mass was encapsulated (Fig. 5). The mass was excised and radical debridement performed. The muscle and superficial fascia were sutured together to prevent shearing at the surgical site and to reduce the possibility of recurrence. Biopsy of the excised mass

revealed a cystic lesion that has the fibrous cystic wall but lacks lining cells (Fig. 6). In the surrounding area, there was fat necrosis, multifocal fibrosis, and aggregation of histiocytes and foreign body type giant cells. At the 1-year follow-up, we found no complication or any evidence of recurrence.

3. Discussion

MLL is a post-traumatic lesion; an effusion consisting of hemolymph and necrotic fat is generated after damage to the capillaries and lymphatics caused by a shear force between the muscle fascia and the subcutaneous layer. After the acute phase subsides, the surrounding tissues become granulated, creating a

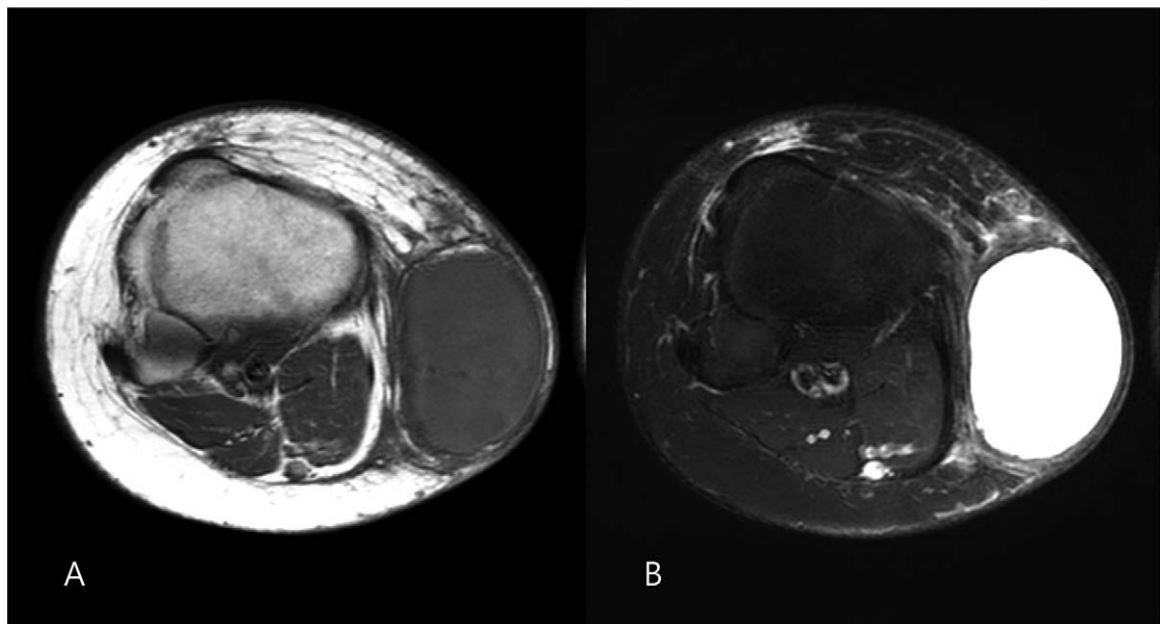


Figure 4. (A) An axial plane T1-weighted MRI image of low, homogeneous signal intensity, and, (B) an axial plane T2-weighted MRI image exhibiting high-level signal change. MRI = magnetic resonance image.

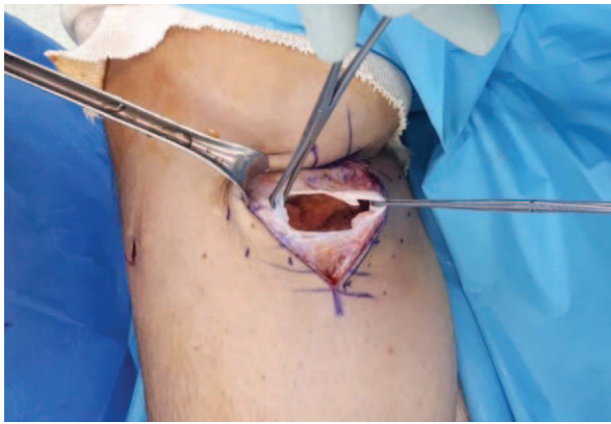


Figure 5. The encapsulated mass containing serous fluid.

type of pseudocyst. The clinical significance is that the internal fluid cannot be absorbed by surrounding tissue; the “mass effect” may induce symptoms, and surgical site infection and recurrence may develop despite treatment.^[6,7]

MLL, as in our case, is usually caused by high-energy trauma such as a motor vehicle accident, but can also develop in those who play contact sports such as football.^[8] Although MLL may be associated with a fracture, MLL is not common and may be missed at initial examination. When the acute phase subsides, the lesion can be palpated on physical examination, but most patients do not have pain. Thus, an MLL should be considered at initial diagnosis. In our patient, the lesion did not cause any symptoms and was not detected because of splint immobilization after operation to repair the fracture. The MLL presented as a painless mobile mass after weaning from the splint. MLLs develop predominantly in areas where the motion of the deep fascia is relatively small, such as the trochanteric region and thigh. Female sex and a body mass index (BMI) > 25 kg/m² are risk factors for MLL because such patients have relatively high proportions of fat.^[9,10] Our patient was male but his BMI was 33.6 kg/m².

MLL of the proximal calf is rare. Vanhegan et al^[11] found that MLLs developed most commonly in the greater trochanter/hip region (30.4%), thigh (20.1%), pelvis (18.6%), and knee

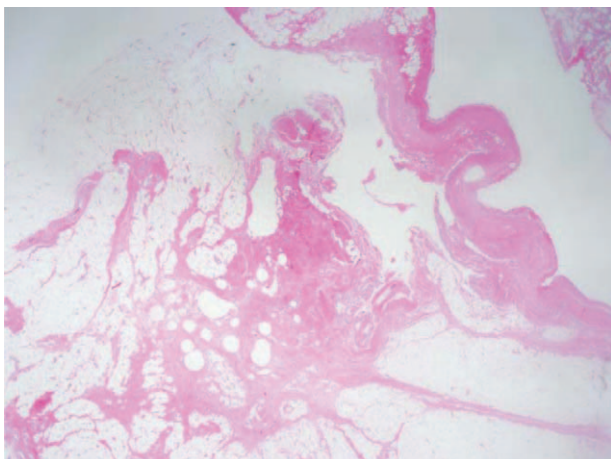


Figure 6. Biopsy of the excised mass revealed a fibrotic pseudocapsule exhibiting fat necrosis but no synovial lining.

(15.7%); only 1.5% occurred in the calf or lower leg. MLL may be undiagnosed or misdiagnosed and may require differential diagnosis from simple bursitis, an abscess, and a soft tissue tumor.

Plain radiography is not specific but is required to explore accompanying lesions such as fractures and to confirm the absence of calcification in the acute phase. US can be performed if an MLL is suspected; MLL presents as a nonspecific fluid collection. However, US is useful to assess damage to surrounding tissue and the outcomes of interventional procedures such as percutaneous aspiration. MRI optimally identifies MLL characteristics and chronicity. Mellado and Bencardino^[12] divided MLLs into 6 types based on the extent of chronicity, tissue composition, and MRI presentation. Using this classification, our patient showed the type I seroma pattern on a homogeneous, hypointense T1-weighted image and a homogeneous, hyperintense T2-weighted image.

MLL requires appropriate treatment; bacterial infection and chronic recurrence are possible. An acute lesion without an open wound or fracture can be treated conservatively via compression banding, sclerotherapy with talc or doxycycline, and percutaneous drainage.^[4,13,14] However, MLL does not respond to steroids (in contrast to bursitis) because a synovial lining is absent.^[15] Surgery with radical debridement effectively treats chronic lesions when conservative treatments fail because of fibrotic capsule formation and persistent lymphatic leakage.^[16] We performed repeated percutaneous drainage and intralesional steroid injections over the 3 months after injury, but these treatments were ineffective; we eliminated the possibility of recurrence via surgical excision and interspace suturing.

Greenhill et al^[17] proposed an MLL treatment algorithm based on chronicity, but surgeons must choose treatment by reference to lesional characteristics and their knowledge of the condition. MLL usually develops in the greater trochanter or pelvis; few reports on surgical removal of MLLs in the proximal calf have appeared. Molnar et al^[18] and Moriarty et al^[19] reported MLLs in the proximal calf. Both reports emphasized that the condition is rare and easily missed, but clinically significant.

4. Conclusion

MLL may occur anywhere after trauma but is unusual in the calf; MLL of the trochanteric region is more common. It is important to diagnose MLL because the complications may include infection, local recurrence, and skin necrosis. Conservative treatment may be effective for acute MLLs. However, because of the possibility of recurrence of chronic lesions, surgical treatment with radical excision and interspace suturing should be considered.

Acknowledgments

The authors would like to thank the Soonchunhyang University Research Fund for support.

Author contributions

Data curation: Yong Cheol Hong.

Resources: Ji-Hye Lee.

Supervision: Hong Seop Lee, Sung Hun Won, Dhong Won Lee.

Writing – original draft: Chang Hyun Kim.

Writing – review & editing: Woo Jong Kim, Ji-Hye Lee.

Chang Hyun Kim orcid: 0000-0002-2539-1058.

References

- [1] Tseng S, Tornetta P3rd. Percutaneous management of Morel-Lavallee lesions. *J Bone Joint Surg Am* 2006;88:92–6.
- [2] Hak DJ, Olson SA, Matta JM. Diagnosis and management of closed internal degloving injuries associated with pelvic and acetabular fractures: the Morel-Lavallee lesion. *J Trauma* 1997;42:1046–51.
- [3] Kalaci A, Karazincir S, Yanat AN. Long-standing Morel-Lavallee lesion of the thigh simulating a neoplasm. *Clin Imaging* 2007;31:287–91.
- [4] Tejwani SG, Cohen SB, Bradley JP. Management of Morel-Lavallee lesion of the knee: twenty-seven cases in the national football league. *Am J Sports Med* 2007;35:1162–7.
- [5] Bonilla-Yoon I, Masih S, Patel DB, et al. The Morel-Lavallee lesion: pathophysiology, clinical presentation, imaging features, and treatment options. *Emerg Radiol* 2014;21:35–43.
- [6] Whitehouse JD, Friedman ND, Kirkland KB, et al. The impact of surgical-site infections following orthopedic surgery at a community hospital and a university hospital: adverse quality of life, excess length of stay, and extra cost. *Infect Control Hosp Epidemiol* 2002;23:183–9.
- [7] Suzuki T, Morgan SJ, Smith WR, et al. Postoperative surgical site infection following acetabular fracture fixation. *Injury* 2010;41:396–9.
- [8] Matava MJ, Ellis E, Shah NR, et al. Morel-lavallee lesion in a professional american football player. *Am J Orthop (Belle Mead NJ)* 2010;39:144–7.
- [9] Hudson DA. Missed closed degloving injuries: late presentation as a contour deformity. *Plast Reconstr Surg* 1996;98:334–7.
- [10] Carlson DA, Simmons J, Sando W, et al. Morel-Lavallee lesions treated with debridement and meticulous dead space closure: surgical technique. *J Orthop Trauma* 2007;21:140–4.
- [11] Vanhegan IS, Dala-Ali B, Verhelst L, et al. Lesion as a rare differential diagnosis for recalcitrant bursitis of the knee: case report and literature review. *Case Rep Orthop* 2012;2012:593193.
- [12] Mellado JM, Bencardino JT. Morel-Lavallee lesion: review with emphasis on MR imaging. *Magn Reson Imaging Clin N Am* 2005;13:775–82.
- [13] Shen C, Peng JP, Chen XD. Efficacy of treatment in peri-pelvic Morel-Lavallee lesion: a systematic review of the literature. *Arch Orthop Trauma Surg* 2013;133:635–40.
- [14] Luria S, Applbaum Y, Weil Y, et al. Talc sclerodhesis of persistent Morel-Lavallee lesions (posttraumatic pseudocysts): case report of 4 patients. *J Orthop Trauma* 2006;20:435–8.
- [15] Li H, Zhang F, Lei G. Morel-Lavallee lesion. *Chin Med J (Engl)* 2014;127:1351–6.
- [16] Padmanabhan E, Rudrappa RK, Bhavishya T, et al. Morel-Lavallee Lesion: case report with review of literature. *J Clin Diagn Res* 2017;11:TD05–7.
- [17] Greenhill D, Haydel C, Rehman S. Management of the Morel-Lavallee lesion. *Orthop Clin North Am* 2016;47:115–25.
- [18] Molnar SL, Recarte A, Villafane O, et al. Morel-Lavallee syndrome of the tibia. *BMJ Case Rep* 2011;2011:
- [19] Moriarty JM, Borrero CG, Kavanagh EC. A rare cause of calf swelling: the Morel-Lavallee lesion. *Ir J Med Sci* 2011;180:265–8.