

이시성 육종: 섬유육종의 과거력을 가진 환자에서 다형성 평활근육종이 새로 발견된 증례 보고

안승기¹ · 최환준¹ · 이현주²

순천향대학교 천안병원 ¹성형외과, ²병리과

Metachronous Sarcoma: A Case of Pleomorphic Leiomyosarcoma in a Patient with a History of Fibrosarcoma

Seung Ki Ahn¹, Hwan Jun Choi¹, Hyun Ju Lee²

Departments of ¹Plastic and Reconstructive Surgery, ²Pathology, Soonchunhyang University Cheonan Hospital, Cheonan, Korea

Metachronous cancers were defined as those that were detected after an interval of more than 6 months. The instance of two histologically distinct sarcomas in one patient is very unusual. A 42-year-old woman presented for evaluation of a painless mass in her right axilla area. She gave a history of operation 8 years ago for treating a fibrosarcoma on her right upper arm at local clinic. Eight years ago, the lesion was widely excised. Magnetic resonance imaging revealed a new generated tumor at her right axilla. After a wide surgical resection, we performed anterolateral thigh free flap for cover the defect. Second neoplasm is leiomyosarcoma. These two neoplasms are 2 histologically distinct tumors. There is no report of a case of metachronous soft tissue sarcoma both pleomorphic leiomyosarcoma and fibrosarcoma in upper extremity within one person. We emphasize the importance of considering the possibility of metachronous sarcoma.

Key Words: Pleomorphic leiomyosarcoma, Metachronous sarcoma, Soft tissue sarcoma, Fibrosarcoma, Anterolateral thigh free flap

Soft tissue sarcomas account for approximately 1% of adult malignancies, with 50% to 60% occurring in the extremities¹. Predominantly in older males, the annual incidence is about 2 to 4 cases per 100,000 population². About two-thirds of all soft tissue sarcoma arise in the limbs, with up to 50% located in the lower limbs, half of which arise in the thighs. The next most common sites

are the upper extremities, followed by the torso, head, and neck³. In the soft tissue sarcoma, there are many subtypes. Metachronous soft tissue sarcomas are very rare case.

Pleomorphic leiomyosarcoma usually appears in middle-aged or older patients and occurs to be less common in the limbs, also. Pleomorphic leiomyosarcoma frequently

Received June 9, 2017, Accepted June 21, 2017

Corresponding author: Hwan Jun Choi

Department of Plastic and Reconstructive Surgery, Soonchunhyang University Cheonan Hospital, 31 Sooncheonhyang 6-gil, Dongnam-gu, Cheonan 31151, Korea

TEL: +82-41-570-2195, FAX: +82-41-574-6133, E-mail: medi619@hanmail.net

This work was supported by the Soonchunhyang University Research Fund.

Copyright © 2017 by Korean Society for Surgery of the Hand, Korean Society for Microsurgery, and Korean Society for Surgery of the Peripheral Nerve. All Rights reserved.

This is an Open Access article distributed under the terms of the Creative Commons Attribution Non-Commercial License (<http://creativecommons.org/licenses/by-nc/4.0/>) which permits unrestricted non-commercial use, distribution, and reproduction in any medium, provided the original work is properly cited.

begin from large blood vessels⁴. And fibrosarcoma appears to be very common in middle-aged and older adult (median age 50 years). Fibrosarcoma most often involves the deep soft tissues of the neck, trunk, head, and sometimes extremities⁵. In the diagnosis of various primary neoplasm, the widely accepted criteria established by Warren and Gates was used, as follows⁶: 1) each of the tumors showed a final picture of malignancy; 2) each was unconnected; and 3) one was a metastatic lesion derived from the other could be excluded might be possible. Synchronous tumors were explained as second primary tumors that were determined within 6 months of the first primary tumor. Metachronous cancers were defined as those that were detected after an interval of more than 6 months. The instance of two histologically distinct

sarcomas in one patient is very unusual. The exist of patients with synchronous and metachronous, histologically distinct sarcomas is reported only few case till now⁷. In this case, we report a case of metachronous soft tissue pleomorphic leiomyosarcoma in a patient with a history of fibrosarcoma.

CASE REPORT

A 42-year-old women presented for evaluation of a painless mass in her right axilla area. She gave a history of operation 8 years ago for treating a fibrosarcoma on her right upper arm at local clinic (We borrowed a slide and reviewed including immune test again.) (Fig. 1). She had none of other medical problem and medical history.

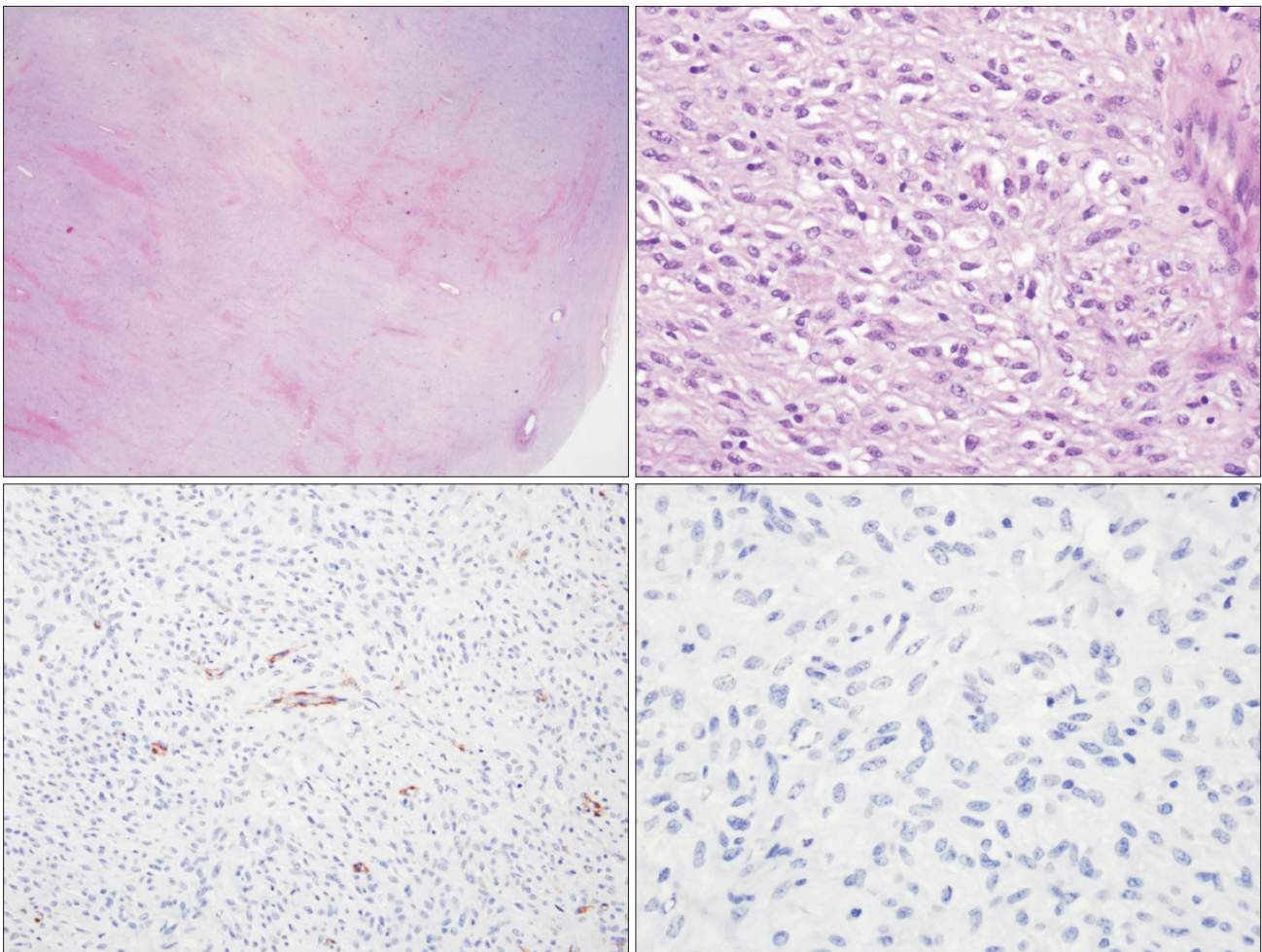


Fig. 1. Microscopic examinations of the fibrosarcoma. The mass is composed of short spindle cell fascicles arranged haphazardly with some eosinophilic collagen fiber (H&E, $\times 200$).

The lesion was widely excised and the latissimus dorsi muscle transposition flap was done for the coverage of the excision site. She did not treated any of other additional options like chemotherapy or radiotherapy. The wound was successfully healed and no recur had been detected during 8 years without adjuvant chemo or radiotherapy.

First, diagnostic partial excisional biopsy was done for the mass and the result was pleomorphic leiomyosarcoma. And then a magnetic resonance imaging revealed a new generated tumor at her right axilla with 4.0×3.0×1.5 cm size (Fig. 2).

A wide surgical resection was performed for secure a free of tumor margin. And axillary lymph node dissection was done. Using anterolateral thigh free flap, the defect site was covered suitable. Histological examination revealed a tumor measuring 4.0×3.0×1.5 cm consisting of malignant cells with mitotic activity of score 2. The surgical resection margin was clear, and there is no metastasis in right axillary lymph node. On detailed immunohistochemical analysis the tumor cells stained positive for smooth muscle actin (SMA), and negative for desmin, S-100 protein, myocin, etc. And also, the tumor cells were stained 30% positive for Ki-67 (Fig. 3, 4). One year later, excision site with free flap coverage was healed well and there was only little scar. Also, there was

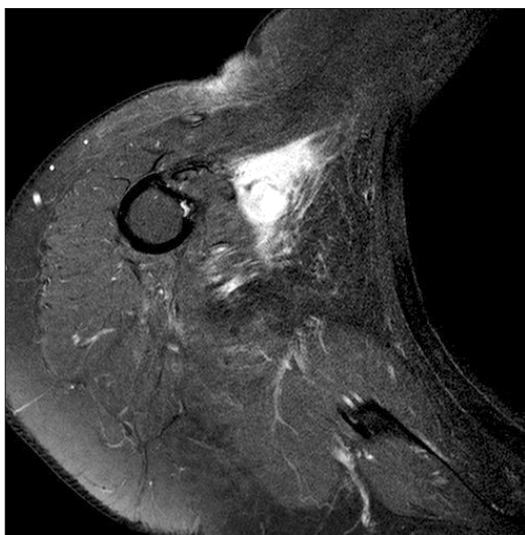


Fig. 2. A magnetic resonance imaging revealed a new generated tumor at her right axilla.

no evidence of recurrence and metastasis (Fig. 5).

DISCUSSION

Soft tissue sarcoma is a rare disease about 1% of adult malignancy. A second primary soft tissue sarcoma occurring in a previously diagnosed adult soft tissue sarcoma patient has; however, 12.5-fold the risk of a similar lesion occurring in a person with no history of the disease⁷. The rate of synchronous/metachronous neoplasms is 7.5% in soft tissue sarcoma patients compared with 1% in the general cancer population⁸. As per Grobmyer et al.⁷, the annual incidence of a non-radiation-induced second primary soft tissue sarcoma is low, and reported to be 4 per 10,000 population. To the best of our knowledge, however, only 24 well described examples of histologically distinct synchronous or metachronous sarcomas have been published. These include 18 examples of synchronous or metachronous soft tissue sarcomas. When a second tumor arises, often the initial clinical suspicion is of recurrent or metastatic tumor. In this case, primary tumor, fibrosarcoma cells are negative for SMA and Ki-67 but secondary tumor, pleomorphic leiomyosarcoma cells are positive for SMA and 30% positive for ki-67. Crucially, the second neoplasm was biopsied and morphological

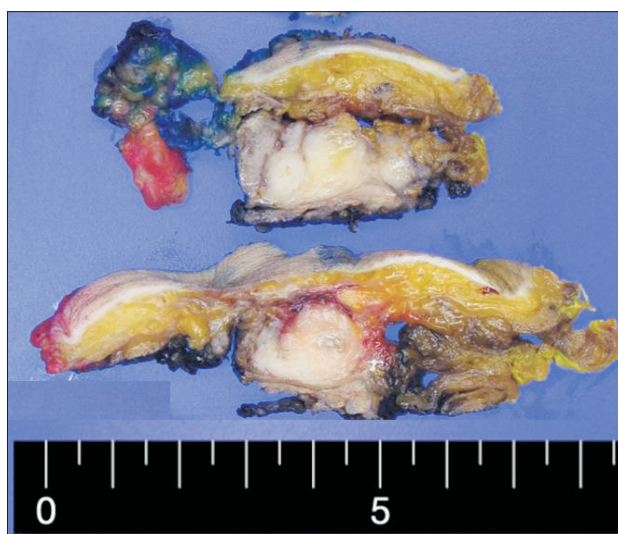


Fig. 3. Gross examination of the pleomorphic leiomyosarcoma. The mass is a well-demarcated nodular, and located between subcutaneous fat tissue and skeletal muscular tissue. The cut surface reveals homogeneous grey whitish solid nature.

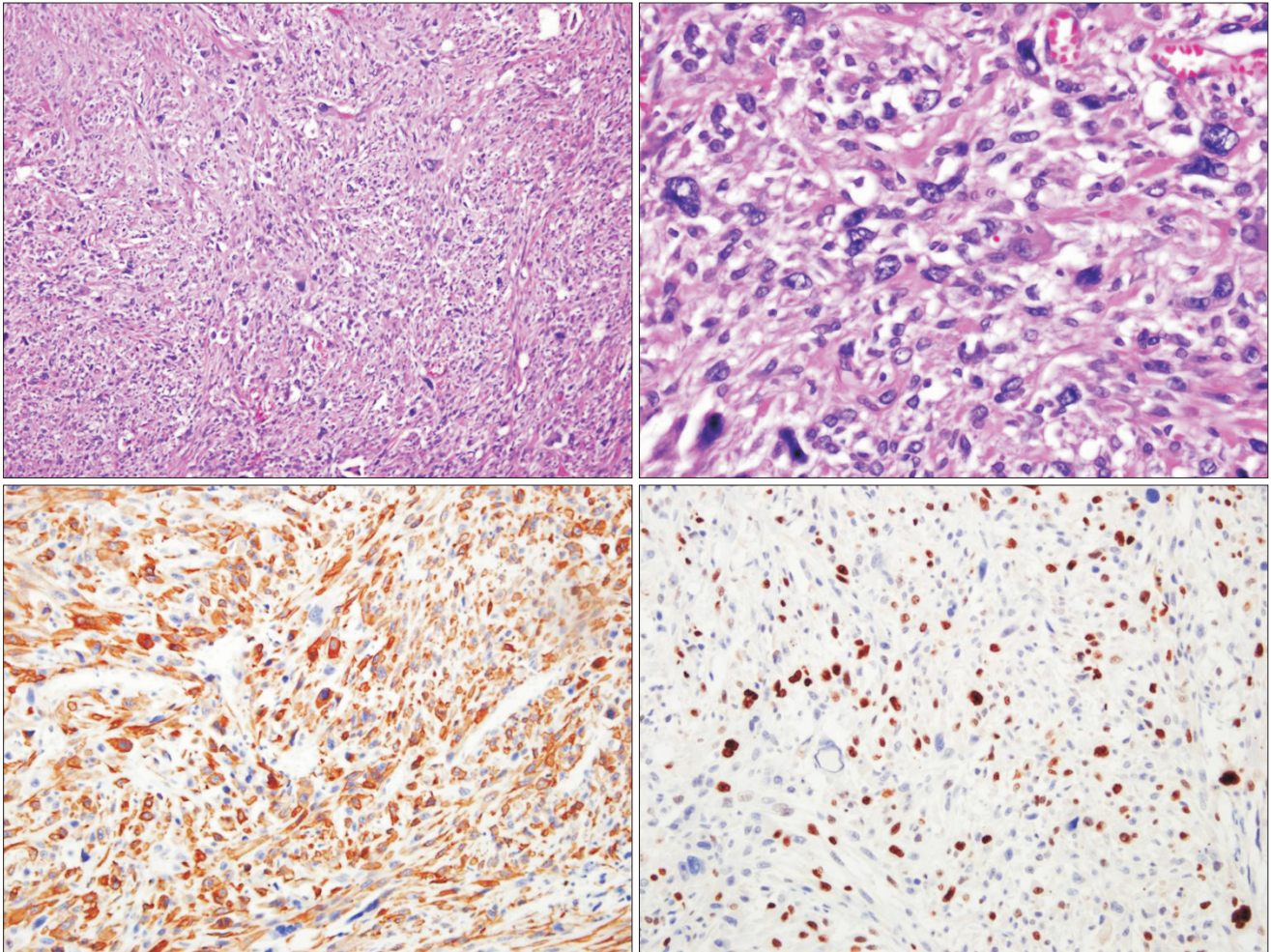


Fig. 4. Microscopic examinations of the pleomorphic leiomyosarcoma. The mass is composed of marked pleomorphic short spindle cells arranged haphazardly (H&E, $\times 400$).

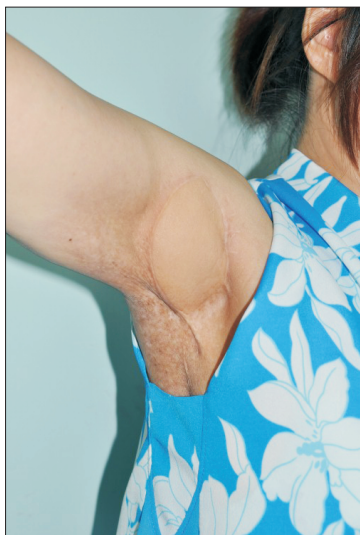

Fig. 5. Excision site with free flap coverage was healed well and there was only little scar. There was no evidence of recurrence and metastasis.

evaluation revealed 2 histologically distinct tumors.

Surgical excision is the first choice treatment for all patients with adult-type, localized soft tissue sarcomas, and it should be performed by an appropriately trained surgeon. The immediate objective of surgery is completely excise the tumor with a margin of normal tissue. What constitutes an acceptable margin of normal tissue is not universally agreed but is commonly accepted as 1 cm soft tissue or equivalent (e.g., a layer of fascia)⁹.

Pleomorphic leiomyosarcoma and fibrosarcoma are relatively common types of sarcoma³. But there is no report of a case of metachronous soft tissue sarcoma both pleomorphic leiomyosarcoma and fibrosarcoma in upper extremity within one person. We emphasize the importance of considering the possibility of a new primary soft tissue

cancer and the decisive role of biopsy and histopathological evaluation when a second tumor arises. The phenomenon of either metachronous or synchronous incidence of multiple soft tissue sarcomas is very rare and systematic reporting of every new case in the literature could contribute to further knowledge of soft tissue tumor's unique behavior.

CONFLICTS OF INTEREST

The authors have nothing to disclose.

REFERENCES

1. Daigeler A, Lehnhardt M, Sebastian A, et al. Metachronous bilateral soft tissue sarcoma of the extremities. *Langenbecks Arch Surg.* 2008;393:207-12.
2. Tukiainen E, Böhling T, Huuhtanen R. Soft tissue sarcoma of the trunk and extremities. *Scand J Surg.* 2003;92:257-63.
3. Pitcher ME, Fish S, Thomas JM. Management of soft tissue sarcoma. *Br J Surg.* 1994;81:1136-9.
4. Dei Tos AP. Classification of pleomorphic sarcomas: where are we now? *Histopathology.* 2006;48:51-62.
5. Folpe AL. Fibrosarcoma: a review and update. *Histopathology.* 2014;64:12-25.
6. Warren S, Gates O. Multiple primary malignant tumors. A survey of the literature and statistical study. *Am J Cancer.* 1932;16:1358-414.
7. Grobmyer SR, Luther N, Antonescu CR, Singer S, Brennan MF. Multiple primary soft tissue sarcomas. *Cancer.* 2004;101:2633-5.
8. Picardo NE, Mann B, Whittingham-Jones P, Shaerf D, Skinner JA, Saifuddin A. Bilateral symmetrical metachronous myxofibrosarcoma: a case report and review of the literature. *Skeletal Radiol.* 2011;40:1085-8.
9. Grimer R, Judson I, Peake D, Seddon B. Guidelines for the management of soft tissue sarcomas. *Sarcoma.* 2010;2010:506182.

이시성 육종: 섬유육종의 과거력을 가진 환자에서 다형성 평활근육종이 새로 발견된 증례 보고

안승기¹ · 최환준¹ · 이현주²

순천향대학교 천안병원 ¹성형외과, ²병리과

이시성 암은 두 종류의 암 사이에 발생기간이 6개월 이상의 차이가 있는 경우로 정의되었다. 한 환자에서 두 개의 조직학적으로 구별되는 육종이 발견되는 예는 매우 드문 경우이다. 42세 여성 환자가 오른쪽 겨드랑이에 통증이 없는 덩이를 주소로 내원하였다. 그녀는 8년 전 오른쪽 팔의 섬유육종을 치료받은 기록이 있었다. 8년 전 섬유육종이 있던 병변은 광범위하게 절제되었다. 자기공명영상에서 오른쪽 겨드랑이에 새로 발생한 종양이 발견되었다. 광범위 절제술을 시행하였고, 발생한 결손부위를 덮기 위해 전외측 대퇴부 유리피판술을 사용하였다. 새로 발생한 종양은 섬유육종이 아닌 다형성 평활근육종으로 밝혀졌다. 이 두 신생물은 조직학적으로 구별되는 각각의 종양이다. 한 사람에서 다형성 평활근육종과 섬유육종의 이시성 육종이 보고된 바는 없다. 우리는 새로운 종양이 발생한 경우에서 이시성 육종의 가능성을 고려해야 한다.

색인단어: 다형성 평활근육종, 이시성 육종, 연부조직 육종, 섬유육종, 전외측 대퇴부 유리피판술

접수일 2017년 6월 9일

게재확정일 2017년 6월 21일

교신저자 최환준

31151, 천안시 동남구 순천향6길 31, 순천향대학교 천안병원 성형외과

TEL 041-570-2195 FAX 041-574-6133 E-mail medi619@hanmail.net