



One-stage reconstruction of full-thickness alar defects with a folded nasolabial island flap

Da Woon Lee¹,
Hyeong Rae Ryu¹,
Hwan Jun Choi^{1,2},
Jun Hyuk Kim¹

¹Department of Plastic and Reconstructive Surgery and ²Institute of Tissue Regeneration, Soonchunhyang University College of Medicine, Cheonan, Korea

Original Article

Background: The reconstruction of large full-thickness alar defects requires complex surgical procedures that are usually performed in two stages, with concomitant disadvantages in terms of patient trauma, surgical risk, and cost. This study presents a functional folded nasolabial island flap (FNIF) that can be used to repair large-sized full-thickness alar defects in a straightforward manner.

Methods: This retrospective study included seven patients who received a FNIF for a full-thickness alar defect between January 2007 and December 2020. The FNIF is different from the conventional nasolabial flap in that it is folded and twisted to achieve nostril reconstruction with a satisfactory three-dimensional mucosal lining in a single stage. The cosmetic and functional results of FNIF were evaluated by both patients and physicians.

Results: The age ranged from 51 to 82 years (mean, 65.6 years). The causes of the defects were squamous cell carcinoma, basal cell carcinoma, and trigeminal trophic syndrome. The nostril lining did not collapse, there was no hypertrophic scarring, and air movement through the nostrils on the flap side was normal. Overall, FNIF produced excellent aesthetic and functional outcomes, with minimal patient discomfort. There were no postoperative complications.

Conclusion: Compared with existing reconstruction methods for large full-thickness alar defects, FNIF can easily achieve aesthetic and functional success in a single-stage procedure. It provides satisfactory results for both the patient and the surgeon.

Abbreviations: BCC, basal cell carcinoma; FNIF, folded nasolabial island flap; SCC, squamous cell carcinoma

Keywords: Nasal cartilage / Reconstructive surgical procedures / Surgical flap

INTRODUCTION

The nose is highly contoured and occupies a central position on the face. These characteristics allow small asymmetries and imperfections of the contour to be easily noticeable [1]. The

nose is also functionally important, as it plays crucial roles in breathing, olfaction, and phonation and is structurally complex. Therefore, nasal reconstruction is a highly challenging surgical procedure.

Complete reconstruction of the nose requires reconstruction of the inner mucosal lining, external nostril lining, and supporting structures [2]. The method of reconstruction should be chosen from the numerous options available based on the patient's needs, the goals of reconstruction, the specific location, and the surgeon's skill with a particular technique [3]. Reconstruction of partial-thickness alar defects can be performed with a simple primary closure or a local flap, but large full-

Correspondence: Jun Hyuk Kim

Department of Plastic and Reconstructive Surgery, Soonchunhyang University College of Medicine, 31 Suncheonhyang 6-gil, Dongnam-gu, Cheonan 31151, Korea

E-mail: psdoctor@schmc.ac.kr

This work was supported by the National Research Foundation of Korea (NRF) grant funded by the Korean government (MSIT) (2021R1G1A1008337) and was supported by the Soonchunhyang University Research Fund.

Received July 31, 2021 / Revised August 6, 2021 / Accepted August 20, 2021

thickness defects require a more complex method, such as a forehead flap or free flap. The subcutaneous pedicled nasolabial flap has been used as a reconstruction method for large full-thickness alar defects. Herbert [4] showed that even a large flap can survive with a narrow subcutaneous pedicle due to the abundant vascular distribution of the nasolabial skin. However, this is a two-stage procedure, which causes significant patient trauma, is laborious for the surgeon, results in proportionate surgical risk, and imposes a substantial financial burden. These limitations highlight the need for improved options. Herein, we introduce a folded nasolabial island flap (FNIF), which is a modification of the nasolabial flap. The FNIF retains all the benefits of a nasolabial flap and addresses its limitations. FNIF can be used to reconstruct alar defects without cartilage graft (a common requirement in nasolabial flaps), allows adequate maintenance of the external nasal valve, and is less time-consuming.

METHODS

Patients

This retrospective study included seven patients treated between January 2007 and December 2020 with an alar defect of 1 cm or more and full-thickness defects that included cartilage, nasal skin, and nasal mucosa between January 2007 and December 2020. The defects in all patients were due to basal cell carcinoma, squamous cell carcinoma, or trigeminal trophic syndrome.

Study design

Delayed flap reconstruction was performed by a single surgeon (JHK) several months after wide excision of the skin cancer. Wide excision was performed with a 3-mm free margin, leading to full-thickness loss of the entire right nasal ala and a cutaneous tissue defect. The assessment of outcomes considered

both aesthetics and function (airway patency). The results were objectively recorded, reflecting the input of the patient and physician. Our evaluation criteria were similar to the assessment tool used by Cook [5], based on photographs of each patient. The assessment scale was divided into 6 points, with scores ranging from 0 to 5 (corresponding to poor, unsatisfactory, satisfactory, good, very good, and excellent). The results are presented in Table 1.

Surgical technique

Wide excision was performed in all patients in this study, resulting in extensive alar defects. In the case of skin cancer, the depth of the tumor was relatively deep; therefore, delayed reconstruction was performed to check the tumor margin in the permanent section. The defects were temporarily covered with a split-thickness skin graft until a delayed reconstruction was performed.

After measuring the required amount of inner mucosal and outer nostril lining, flap harvesting was planned on the ipsilateral side to sufficiently cover the defect. The width of the nasolabial fold was designed based on the size of the defect (Fig. 1A). The FNIF uses the alar crease as a pivot point and gently folds to restore the convex shape of the lateral crus. For sufficient flap transposition and interpolation, the medial incision of the flap should be made at the lateral border of the defect (Fig. 1B). The inferolateral incision endpoint of the flap must be long enough to allow the formation of a nostril rim after adequate folding of the pedicled flap. After the incision, the adjacent medial cheek was undermined and advanced to close the donor defect. FNIF was elevated with a certain amount of subcutaneous fat tissue (Fig. 1C). The flap was elevated and remained attached to a narrow pedicle containing multiple arterial and venous perforators. In some cases, when the flap was not large, the perforators of the lateral nasal artery were used as the pedicle. If there was no reliable vein, the adipofascial tissue was

Table 1. Summary of patients

Patient	Sex	Age (yr)	Cause	Location	Flap size (cm)	Additional debulking procedure	Complication	Physician Assessment Scale		Patient Satisfaction Scale	
								Cosmetic	Functional	Cosmetic	Functional
1	M	52	BCC	Nasal ala	2.5 × 7	0	None	4	5	4	5
2	M	51	Trigeminal trophic syndrome	Nasal ala	3 × 7	0	None	3	5	4	3
3	F	64	SCC	Nasal floor, nasal ala	2 × 7	X	None	5	5	5	5
4	M	72	BCC	Nasal floor, nasal ala	3 × 7.5	X	None	5	5	5	5
5	F	79	SCC	Nasal ala	3 × 6	X	None	5	5	5	4
6	M	82	SCC	Nasal ala	3 × 5.5	0	None	4	5	5	4
7	M	59	BCC	Nasal ala	2 × 6.5	0	None	5	4	5	5

The assessment scale was divided into 6 points, with scores ranging from 0 to 5 (corresponding to poor, unsatisfactory, satisfactory, good, very good, and excellent). M, male; F, female; BCC, basal cell carcinoma; SCC, squamous cell carcinoma.

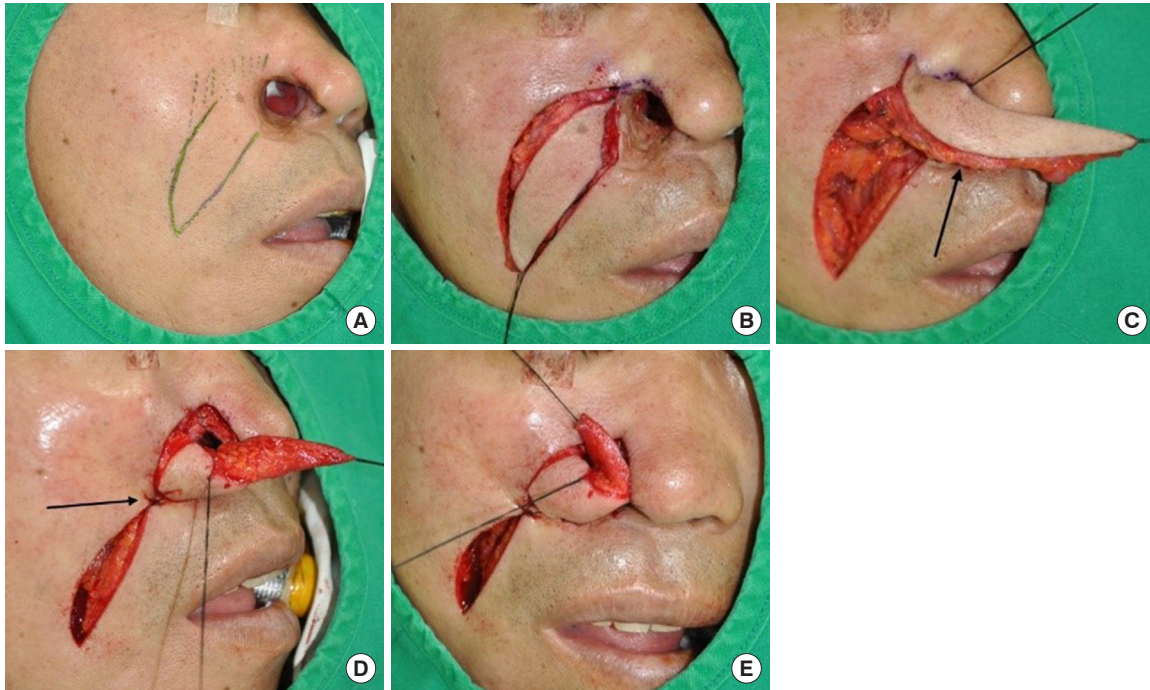


Fig. 1. Intraoperative photographs of a 52-year-old man with a full-thickness defect of the right nasal ala (Patient 1). (A) The incision line was designed in consideration of the circumference and antero-posterior size of the defect. (B) The flap incision is started at the lateral border of the alar defect and was proceeded in the order of superomedial and lateral incision of the nasolabial fold. (C) After flap elevation, the flap includes a certain amount of subcutaneous fat tissue (black arrow). (D) At the pivot point of the flap, two stitches are performed (black arrow). (E) Superfluous subcutaneous fat is removed while preserving the subdermal plexus. To recreate the lateral nostril lining, the flap is transposed, inverted, and the distal half of the flap is folded to the defect site.

partially included and raised to prevent venous congestion. After elevation of the flap, we marked a turning point on the alar crease pivot, and the flap was transposed and folded (Fig. 1D). The flap was sutured in an appropriate position while evaluating whether the folded flap properly formed a nostril lining that maintained a proper lateral alar base and airway patency. To improve aesthetic outcomes, scar revision and delayed flap debulking procedures were performed in four cases. The subdermal plexus and angular artery at the pivot point were preserved (Fig. 1E). If there was a thick area in the nostril rim of the flap, the thick area of the FNIF was defatted, and the nostril was reconstructed to make it shallow. A defatted flap is easy to fold and has a high chance of achieving good aesthetic results. To recreate the lining of the nostril rim, the island flap was transposed and inverted, and the distal half of the flap was folded onto the defect site with several 5-0 Maxon (Covidien, Dublin, Ireland) sutures and multiple simple interrupted 6-0 Dermalon (Covidien) sutures (Fig. 2E). After the flap inset, the surgeon could properly move the alar base laterally and had an adequate opportunity to resolve any displacement and asymmetry with sufficient free tissue.

As in many existing nasolabial flap procedures, we did not perform a cartilage graft for reasons similar to those for Spear's

flap. Instead, we maintained the framework of the nostril lining with the volume of the flap itself. The flap donor site was then sutured linearly. Approximately 2 weeks after surgery, plastic tubing was temporarily maintained for 3 months in the nostril to prevent the nostril lining and external nasal valve from collapsing and to maintain airway patency. Postoperatively, no nasal packing was performed.

RESULTS

The age of the patients ranged from 51 to 82 years (mean, 65.6 years). Five patients were male, and two were female. Five patients were smokers. Six patients had been diagnosed with skin cancer (basal cell carcinoma and squamous cell carcinoma), and one patient had trigeminal trophic syndrome after herpes zoster infection. All operations were performed under general anesthesia. For oncologic surveillance, all patients received a split-thickness skin graft during the first operation, which was removed during the following flap operation. The mean flap size was 2.6 × 6.6 cm. No complications occurred (Table 1).

The flap was then monitored and cleaned daily. One week after the operation, the flap was fully viable without minor wound complications, such as flap congestion or infection. The

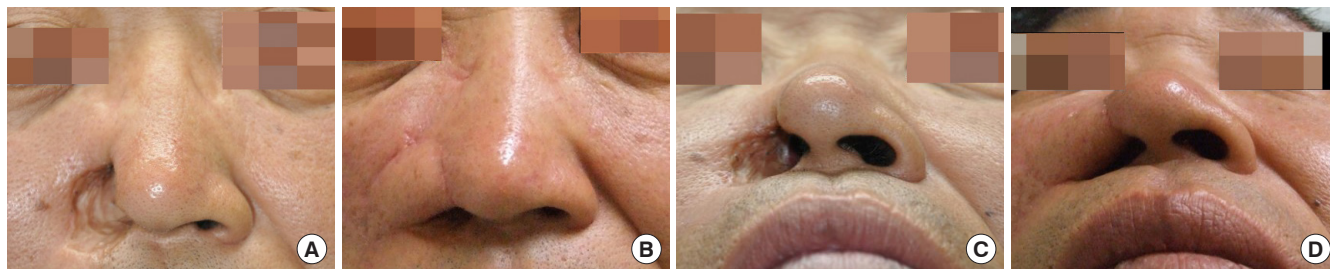


Fig. 2. A 52-year-old man with a full-thickness defect of the right nasal ala due to basal cell carcinoma (Patient 1). (A, C) Preoperative photographs. The patient underwent a folded nasolabial island flap. (B, D) Six-month postoperative photographs before the debulking procedure. The patient is satisfied with the result, but there is a mild asymmetry. The additional debulking procedure is performed for cosmetic purposes.

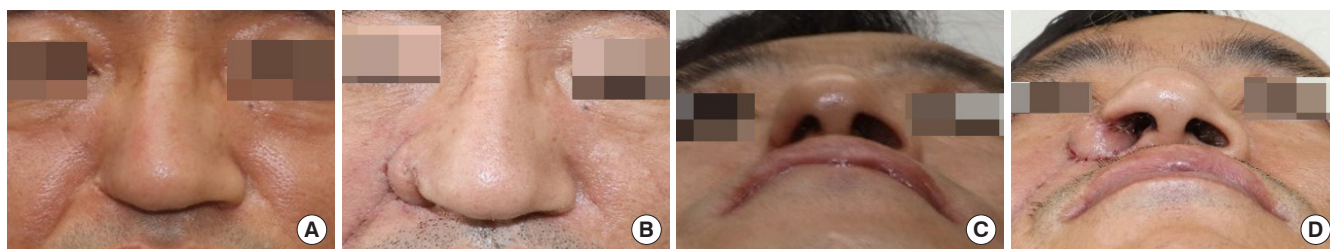


Fig. 3. A 51-year-old man with a full-thickness defect of the right nasal ala due to trigeminal trophic syndrome (Patient 2). (A, C) Preoperative photographs. (B, D) Six-month postoperative photographs before the debulking procedure. Asymmetry was observed and an additional debulking procedure was performed for cosmetic purposes.

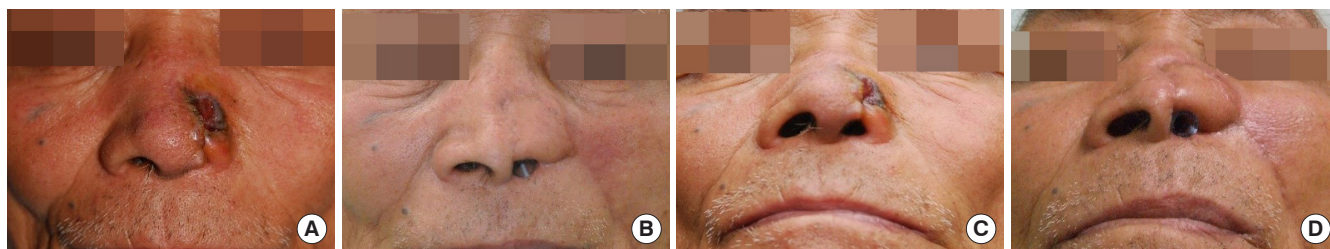


Fig. 4. A 72-year-old man with a full-thickness defect of the right nasal ala and floor due to basal cell carcinoma (Patient 4). (A, C) Preoperative photographs. (B, D) Six-month postoperative photographs. The patient is satisfied with the result, and an additional debulking procedure is unnecessary.

alar rim was slightly thicker than ideal in the worm's view, but there were no functional problems, and the airway patency was well maintained.

Three months after surgery and flap maturation, the inserted tube was removed. The nostril lining did not collapse, and there was no hypertrophic scarring. The nasolabial fold of the flap elevation site was faint compared to that on the contralateral side, but the fold line was visible. Air movement through the nostrils on the flap side was comfortable and unobstructed, as was the case on the contralateral side. Patients did not experience discomfort during inhalation or expiration. All patients were satisfied with the functional and aesthetic results of the operation (Figs. 2-4). Based on the appearance of the patients before and after the operation, other physicians determined the aesthetic outcomes to be "very good" or "excellent" (Table 1).

DISCUSSION

Reconstruction of alar defects is challenging due to the single-subunit structure of the ala and its limited mobility [6]. Causes of nasal defects include traumatic injury, viral infections, and tumor resection [7]. A wide range of reconstruction methods for alar defects can be chosen according to the size and depth of the defect, including primary repair, skin graft, composite auricular graft, cheek advancement, septal mucosal flap, and paramedian forehead flap. However, there are limited flap options for full-thickness alar defects.

The septal mucoperichondrial flap and forehead flap are suitable reconstructive options for full-thickness alar defects; however, they are technically challenging [1]. The septal mucoperichondrial flap is an example of a lining flap, and a thinner lin-

ing of the nostril can be expected with this technique than with other local flaps. However, it requires skilled techniques and a steep learning curve, and it is difficult to accurately predict the symmetry and surgical outcomes. The median forehead flap is widely used to reconstruct defects in all nose subunits with a wide range of sizes [8]. However, the most substantial drawback of this flap is the donor site scar that forms in the central forehead area, especially in Asian populations [9]. Unlike Caucasians, the nose of Asians generally has a flat, wide base of the bony pyramid, less muscle volume, and a flatter glabella [10]. Most importantly, Asians have thicker skin than Caucasians, and scars are more pronounced when forehead flaps are made [11]. The maximum possible width of the donor site of the median forehead flap is approximately 4 cm, but if the width is more than 2 cm, it is considered aesthetically unsatisfactory [12]. Nasolabial flaps are generally less preferable for Caucasian men due to the dense beard and differences in skin texture.

The ear cartilage graft is often used to prevent the collapse of the nostril lining; by doing so, alar defects can be easily reconstructed using a two-layer composite graft [13,14]. A cartilage graft is also used to achieve normal airway patency and appropriate contours [1]. However, in a retrospective analysis of 13 patients who underwent free cartilage graft, van der Eerden et al. [15] reported unsatisfactory aesthetic outcomes in 23% of cases. Cartilage grafts also have a risk of infection (i.e., chondritis) and discoloration. Therefore, satisfactory results cannot be achieved using cartilage composite grafts.

The Spear flap is an excellent, aesthetically impressive, one-step reconstructive method for full-thickness lateral alar defects with a “turn over” nasolabial flap. It hides the flap donor site scars within the nasolabial folds. In addition, the flap pedicle can be preserved at the alar base, and the proximal half of the flap can be used for the internal mucosal lining, while the distal half can be used for nostril lining [16]. It is initially sutured from the alar base to the columella to form a mucosal lining and then folded to form an appropriate outer nostril lining. The framework of the folded flap is satisfactory; therefore, no cartilage graft is required [5]. However, it may not be a good option for Asians, who have thicker skin than Caucasians, as it can induce severe asymmetry. A sliding flap similar to the nasolabial flap is based on the anterior superior subcutaneous pedicle. The superomedial portion of the flap was used to make the outer nostril lining, and the lower portion was partially defatted and inset at the site of the alar defect [17]. The Spear flap generally requires flap revision, such as flap thinning and medial shift of the alar base after the flap has stabilized [2].

Yoon et al. [18] described facial artery perforator-based nasolabial island flaps for the reconstruction of perinasal defects. In

that study, defects on the nasal dorsum, columella, and ala were reconstructed using nasolabial flaps with 120°–180° rotation. Our study is different from the study by Yoon et al. in that we only included patients with full-thickness skin defects. Our method can cover the inner mucosal lining by folding the distal end of the nasolabial flap to prevent the collapse of the nostril.

Taken together, our FNIF method has several advantages. First, in patients with full-thickness defects, the complex structures of the inner mucosal defect, architectural support, and outer nostril lining are reconstructed at once rather than in two stages. As a result, patients can avoid unnecessary additional operations, thus reducing morbidity and medical costs. Furthermore, it is also possible to correct the airway patency problems and asymmetry that appear in the existing transposition flap by promptly performing an appropriate debulking procedure immediately after flap inset, rather than later during postoperative follow-up. Because this folding flap is composed of two layers containing the dermis and subcutaneous fat, it maintains desirable stiffness and is structurally stable. Second, the FNIF is technically easier to perform than many existing reconstruction approaches for large and complex alar defects. The folding position of the FNIF can be freely adjusted according to the size of the alar defect and the projection of the tip. Third, a composite cartilage graft is unnecessary for the FNIF because the structure and convex shape of the lateral ala remain stable for a long period postoperatively without cartilage. Finally, FNIF preserves the sensory nerve, unlike the two stage flap methods, which cause sensory loss.

In this study, there were no complications, such as infection or flap congestion. Blood flow around the ala was abundant, and there were numerous subcutaneous perforators. Therefore, the flap perfusion was adequate, and the chances of flap survival were high.

However, the FNIF described herein has several disadvantages. First, the newly reconstructed ala remained unnaturally thick for a long period and showed asymmetry as the alar base moved laterally. However, if asymmetry causes discomfort, the alar base can be medialized using a small Z-plasty or transposition flap. This is because the folding flap has been reconstructed to be sturdy and thick to maintain the proper strength of the nostril lining. Second, the tubing should be maintained in a specific location for more than 1 month to maintain the size of the nostril after reconstruction. Finally, our technique causes a loss of fat volume of the nasolabial fold corresponding to the amount of tissue used in flap elevation, resulting in asymmetry of the cheeks. Therefore, if possible, the scar should be positioned to align with the nasolabial fold, and the flaps should not be elevated with excess fat. Favorable aesthetic results can be

achieved in donor site closure by forming a depressed scar through intentional suture inversion and creating an appropriate nasolabial fold.

This study has some limitations. First, it included a small number of patients, making it impossible to perform statistical analysis. Various surgical methods to cover alar defects have been discussed above, but surgical outcomes have not been compared with those obtained using other methods. Further studies are warranted to address these limitations.

The FNIF is different from the conventional nasolabial flap in that the FNIF is folded and twisted to achieve nostril reconstruction with a mucosal lining in three dimensions in one stage. The alar base can be successfully reconstructed using the FNIF, providing excellent aesthetic results and preserving nasal airway function. Despite the shortcomings mentioned above, our study demonstrates that FNIF is an effective, simple, and easy reconstruction method for large full-thickness alar defects.

NOTES

Conflict of interest

Hwan Jun Choi and Jun Hyuk Kim are editorial board members of the journal but were not involved in the peer reviewer selection, evaluation, or decision process of this article. No other potential conflicts of interest relevant to this article were reported.

Ethical approval

The study was approved by the Institutional Review Board of Soonchunhyang University Cheonan Hospital (IRB No. 2021-07-037) and performed in accordance with the principles of the Declaration of Helsinki. The informed consent was waived because this study design is a retrospective chart review.

Patient consent

The patients provided written informed consent for the publication and the use of their images.

ORCID

Da Woon Lee <https://orcid.org/0000-0002-6969-5643>
Hyeong Rae Ryu <https://orcid.org/0000-0003-0962-2407>
Hwan Jun Choi <https://orcid.org/0000-0002-0752-0389>
Jun Hyuk Kim <https://orcid.org/0000-0002-0266-8480>

Author contribution

Investigation: Da Woon Lee. Supervision: Jun Hyuk Kim, Hwan Jun Choi. Data curation: Hyeong Rae Ryu. Formal analysis: Da Woon Lee. Project administration: Da Woon Lee. Writing - original draft: Da Woon Lee. Writing - review & editing:

Da Woon Lee, Hyeong Rae Ryu. All authors read and approved the final manuscript.

REFERENCES

1. Driscoll BP, Baker SR. Reconstruction of nasal alar defects. *Arch Facial Plast Surg* 2001;3:91-9.
2. Griffin GR, Chepeha DB, Moyer JS. Interpolated subcutaneous fat pedicle melolabial flap for large nasal lining defects. *Laryngoscope* 2013;123:356-9.
3. Park YJ, Kwon GH, Kim JO, Ryu WS, Lee KS. Reconstruction of nasal ala and tip following skin cancer resection. *Arch Craniofac Surg* 2019;20:382-7.
4. Herbert DC. A subcutaneous pedicled cheek flap for reconstruction of alar defects. *Br J Plast Surg* 1978;31:79-92.
5. Cook JL. Reconstruction of a full-thickness alar wound with a single operative procedure. *Dermatol Surg* 2003;29:956-62.
6. Klinger M, Maione L, Villani F, Caviggioli F, Forcellini D, Klinger F. Reconstruction of a full-thickness alar wound using an auricular conchal composite graft. *Can J Plast Surg* 2010;18:149-51.
7. Lim J, Oh J, Eun S. Flap reconstruction of soft tissue defect after resecting a huge hemangioma of the nose. *Arch Craniofac Surg* 2020;21:69-72.
8. Kim ES, Heo JW, Yang CE, Kim J, Kim SW. Correction of a nasal soft triangle deficiency as a complication of augmentation rhinoplasty. *Arch Craniofac Surg* 2021;22:161-3.
9. Asaria J, Pepper JP, Baker SR. Key issues in nasal reconstruction. *Curr Opin Otolaryngol Head Neck Surg* 2010;18:278-82.
10. Fujiwara M. One-stage reconstruction of an alar defect using a bilobed nasolabial-nasal tip flap based on the aesthetic subunits in Orientals: case report. *Aesthetic Plast Surg* 2004;28:13-6.
11. Uchinuma E, Matsui K, Shimakura Y, Murashita K, Shioya N. Evaluation of the median forehead flap and the nasolabial flap in nasal reconstruction. *Aesthetic Plast Surg* 1997;21:86-9.
12. Tardy ME Jr, Sykes J, Kron T. The precise midline forehead flap in reconstruction of the nose. *Clin Plast Surg* 1985;12:481-94.
13. Yoon SM, Lee DW, Nam SM, Wee SY, Jeong HG, Choi CY. Four limb shaped auricular chondrocutaneous composite graft for the alar and the columellar defects. *Arch Aesthetic Plast Surg* 2017;23:149-54.
14. Qian C, Yaodong X, Xiaoming H, Shaochong F, Yiqing Z. Repair of full-thickness alar defects. *Dermatol Surg* 2012;38:1639-44.
15. van der Eerden PA, Verdam FJ, Dennis SC, Vuyk H. Free cartilage grafts and healing by secondary intention: a viable reconstructive combination after excision of nonmelanoma skin

- cancer in the nasal alar region. Arch Facial Plast Surg 2009;11:18-23.
16. Spear SL, Kroll SS, Romm S. A new twist to the nasolabial flap for reconstruction of lateral alar defects. Plast Reconstr Surg 1987;79:915-20.
 17. Pers M. Cheek flaps in partial rhinoplasty: a new variation: the in-and-out flap. Scand J Plast Reconstr Surg 1967;1:37-44.
 18. Yoon TH, Yun IS, Rha DK, Lee WJ. Reconstruction of various perinasal defects using facial artery perforator-based nasolabial island flaps. Arch Plast Surg 2013;40:754-60.