

Swept-source optical coherence tomography angiography findings of diabetic papillopathy after intravitreal bevacizumab



In Hwan Cho^a, Dae Joong Ma^{b,c,*}

^a Department of Ophthalmology, Soonchunhyang University Hospital Cheonan, Cheonan-si, Chungcheongnam-do, Republic of Korea

^b Department of Ophthalmology, Jeju National University College of Medicine, Jeju-si, Jeju-do, Republic of Korea

^c Department of Ophthalmology, Hallym University Kangnam Sacred Heart Hospital, Seoul, Republic of Korea

ARTICLE INFO

Keywords:

Diabetic papillopathy
Swept-source optical coherence tomography angiography
Bevacizumab

ABSTRACT

Purpose: We report a case of diabetic papillopathy (DP) treated with intravitreal bevacizumab injections and evaluated for disc vessel changes using swept-source optical coherence tomography angiography (SS-OCTA).

Observations: A 52-year-old man was referred with a 1-week history of acute painless decreased vision in both eyes (OU). His best-corrected visual acuity (BCVA) was 20/40 in the right eye (OD) and 20/100 in the left eye (OS). Fundus examination showed swollen optic discs with superficial radially oriented telangiectatic vessels, peripapillary splinter hemorrhages, and hard exudates OU. On SS-OCTA, B-scan images displayed blood flow signals in the thickened retinal nerve fiber layer (RNFL) of the optic disc and superficial RNFL slab images displayed radially oriented telangiectatic vessels OU. Laboratory tests revealed previously unknown diabetes, and we diagnosed the patient with DP OU. Two weeks after an intravitreal injection of bevacizumab OS, the disc swelling, radially oriented telangiectatic vessels, and peripapillary splinter hemorrhages had decreased OS. The superficial RNFL slab OS also depicted decreased radially oriented telangiectatic vessels. However, OD showed no interval changes. Two weeks after an intravitreal bevacizumab injection OD, improved BCVA, decreased disc swelling, radially oriented telangiectatic vessels, and peripapillary splinter hemorrhages were observed OU. The superficial RNFL slab also showed decreased radially oriented telangiectatic vessels OU.

Conclusions and importance: This case showed that bevacizumab is a useful treatment option for DP as they resolve underlying optic nerve capillary vasculopathy. SS-OCTA demonstrated resolved superficial telangiectatic vessels of the optic disc which has not been previously described.

1. Introduction

Diabetic papillopathy (DP) is characterized by unilateral or bilateral optic disc swelling with no detectable etiology other than diabetes mellitus (DM). It is a self-limiting condition that usually resolves over a period of 2–10 months without significant visual sequelae.¹ There is no validated treatment for DP. Serial examination is the most common management because of the benign nature of this condition.² A few recent case reports showed that periocular corticosteroid, intravitreal corticosteroid, and intravitreal anti-vascular endothelial growth factor (VEGF) injections were effective in improving optic disc swelling and visual acuity.^{2–6}

DP is accompanied by a disc vessel change with superficial fine telangiectatic vessels, which are presumed to be dilated preexisting vessels.⁷ These disc vessel changes are believed to reflect the underlying

mechanism of DP. In addition, these superficial telangiectatic vessels of the optic disc are clinically relevant because they can be misdiagnosed as neovascularization of the disc, which requires intensive intervention.

However, there have been no studies evaluating disc vessel changes in DP using swept-source optical coherence tomography angiography (SS-OCTA) after intervention. Herein, we present a case of DP treated with intravitreal bevacizumab injections and evaluated for disc vessel changes on SS-OCTA.

2. Case report

A 52-year-old man was referred with a 1-week history of acute painless decreased vision in both eyes (OU). He had well-controlled hypertension but no other known medical disease. His best-corrected visual acuity (BCVA) was 20/40 in the right eye (OD) and 20/100 in the

* Corresponding author. Department of Ophthalmology, Hallym University Kangnam Sacred Heart Hospital, 1, Singil-ro, Yeongdeungpo-gu, Seoul, 07441, Republic of Korea.

E-mail address: daejoongma@hallym.or.kr (D.J. Ma).

<https://doi.org/10.1016/j.ajoc.2020.100748>

Received 5 February 2020; Received in revised form 7 May 2020; Accepted 14 May 2020

Available online 16 May 2020

2451-9936/ © 2020 The Authors. Published by Elsevier Inc. This is an open access article under the CC BY-NC-ND license

(<http://creativecommons.org/licenses/by-nc-nd/4.0/>).

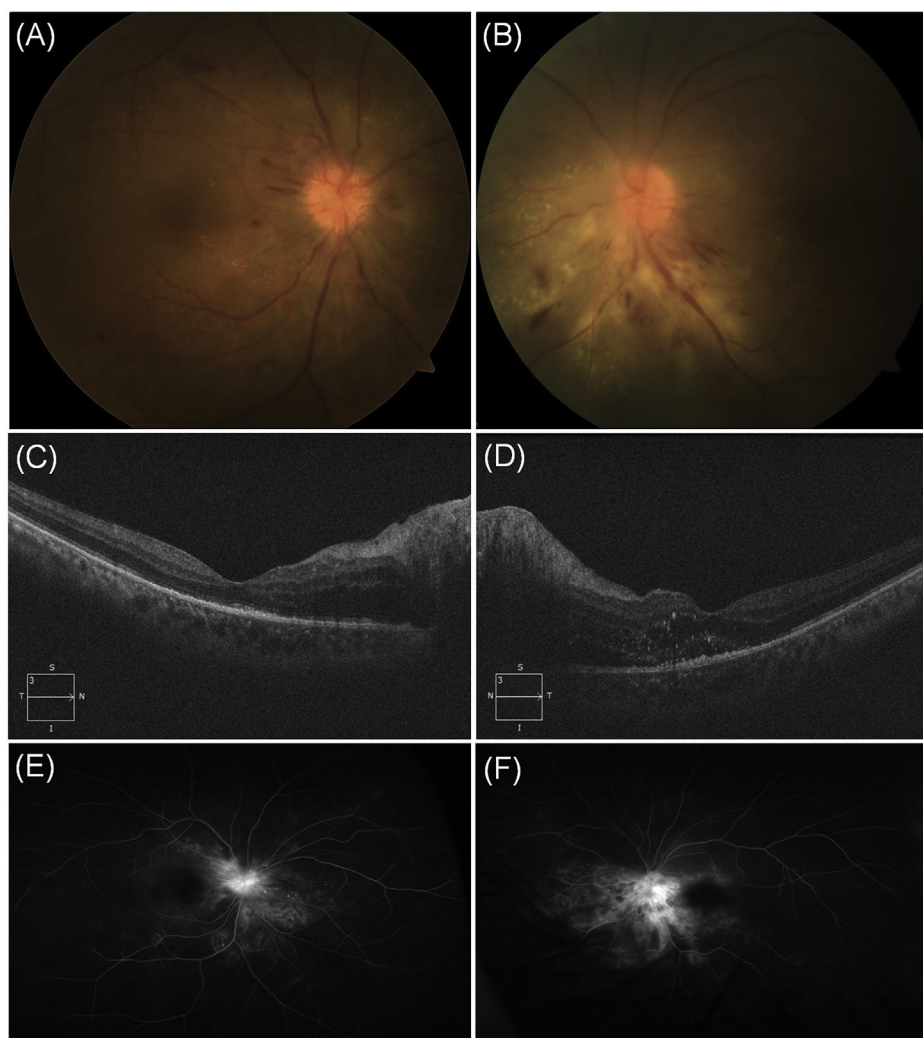


Fig. 1. Fundus photography revealed a swollen optic disc, splinter hemorrhages, and superficial dilated vessels over the optic disc in both eyes (OU) (A, B) Optical coherence tomography revealed a significant increase in retinal nerve fiber layer thickness OU (C, D) and serous macular detachment and macular edema in the left eye (D) Ultra-wide-field fluorescein angiography showed early hyperfluorescence as fluorescein leaks from the disc vessels and microaneurysms OU (E, F). The first column (A, C, E) corresponds to the right eye and the second column (B, D, F) to the left.

left eye (OS). The intraocular pressure was 20 mmHg OU. Anterior segment examination revealed no remarkable findings. There were no relative afferent pupillary defects (APD). Fundus examination showed swollen optic discs with superficial radially oriented telangiectatic vessels, peripapillary splinter hemorrhages, and hard exudates OU (Fig. 1A and B). Optical coherence tomography (OCT) revealed a significant increase in the retinal nerve fiber layer (RNFL) thickness OU and serous macular detachment and macular edema (ME) OS (Fig. 1C and D). Ultra-wide-field fluorescein angiography (FA) showed early hyperfluorescence of the optic disc and microaneurysms OU (Fig. 1E and F).

Optic disc-centered 3×3 -mm SS-OCTA (PLEX Elite 9000; Carl Zeiss Meditec, Inc., Dublin, CA, USA) scans were acquired to evaluate disc vessel changes. B-scan image displayed blood flow signals in the thickened RNFL of the optic disc OU (Fig. 2C and D). There were no blood flow signals above the vitreoretinal interface (vitreoretinal interface [VRI], blue dashed line). A superficial RNFL slab was manually demarcated between VRI and the large disc vessels (white dashed lines in Fig. 2C and D), which displayed radially oriented telangiectatic vessels OU (Fig. 2E and F). The VRI slab image depicted no signal flow (Fig. 2G and H). The whole retina en face image did not show distortion or obscuration of the large vessels (Fig. 2I and J). Humphrey central 30-2 visual field examination showed normal findings OD and mild

depression OS. Pattern visual evoked potential showed normal findings OU.

His blood pressure was 133/86 mmHg. Clinical neurologic examinations, including brain magnetic resonance imaging, were unremarkable. Laboratory tests, including work-ups for inflammation, infection, and connective tissue disease, showed no abnormalities other than elevated blood glucose level and glycated hemoglobin. This patient was newly diagnosed with DM, DP OU, diabetic retinopathy OU, and diabetic ME (DME) OS.

We administered an intravitreal injection of bevacizumab (Avastin; Genentech Inc., San Francisco, CA; 1.25 mg/0.05 mL) OS for DME. After 2 weeks, BCVA improved to 20/50 OS. The disc swelling, radially oriented telangiectatic vessels, and peripapillary splinter hemorrhages decreased OS (Fig. 3B). The OCT image showed decreased subretinal fluid and macular edema OS. The superficial RNFL slab image also depicted decreased radially oriented telangiectatic vessels OS (Fig. 3D). However, BCVA, optic disc configuration, and SS-OCTA findings showed no interval changes OD (Fig. 3A and C).

Since the patient experienced improved BCVA OS after the intravitreal bevacizumab injection, he wanted an intravitreal bevacizumab injection OD. After obtaining written informed consent following an extensive discussion of the risks, benefits, and alternatives to off-label use of the intravitreal bevacizumab injection for DP, we

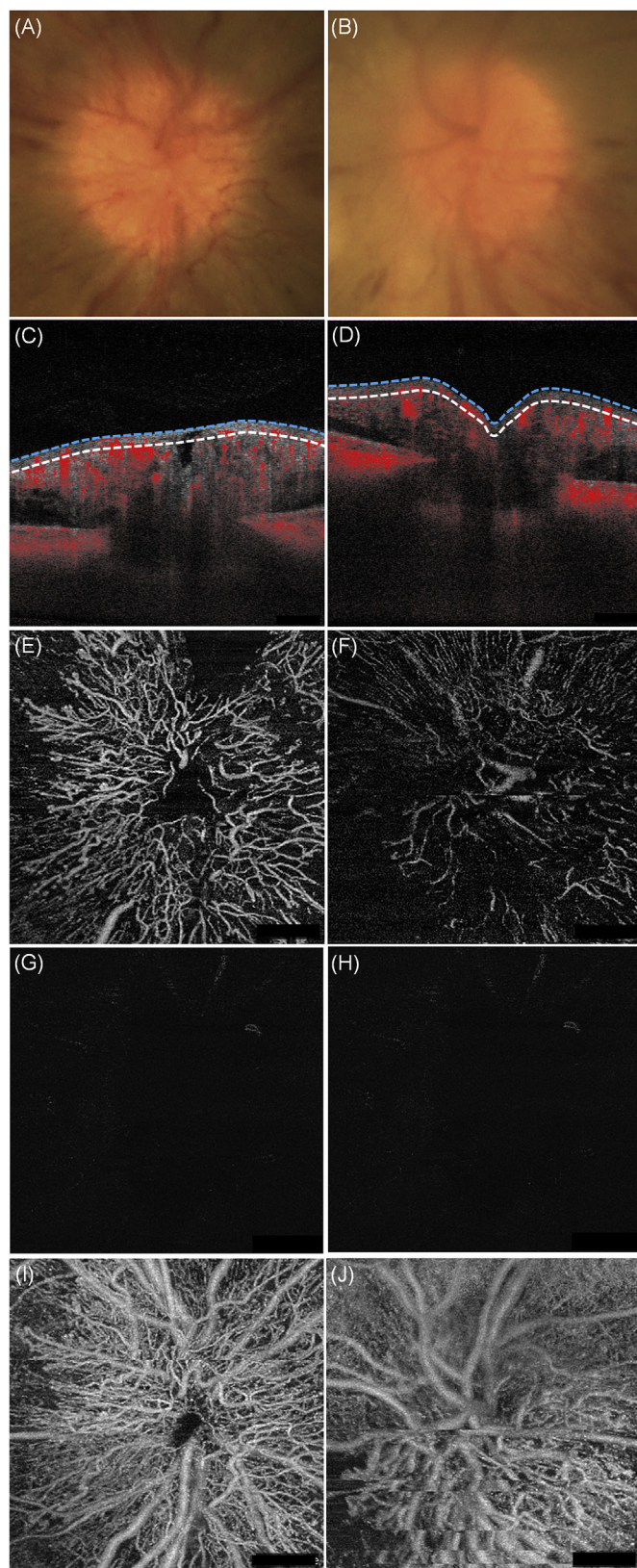


Fig. 2. Magnified images of the optic disc (A, B). The swept-source optical coherence tomography angiography B-scan image displayed blood flow signals in the thickened retinal nerve fiber layer (RNFL) of the optic disc but no flow signals above the vitreoretinal interface (VRI, blue dashed line) in either eye (C, D). Superficial RNFL slab (between blue and white dashed lines in C and D) images show radially oriented telangiectatic vessels in both eyes (E, F). VRI slab images depicted no signal flow in either eye (G, H). The whole retina en face image did not show distortion or obscuration of the large vessels (I, J). The first column (A, C, E, G, I) corresponds to the right eye and the second column (B, D, F, H, J) to the left. (For interpretation of the references to colour in this figure legend, the reader is referred to the Web version of this article.)

The superficial RNFL slab also depicted decreased radially oriented telangiectatic vessels OU (Fig. 3G and H). No further follow-ups were possible for this patient.

3. Discussion

The exact pathogenesis of DP is not clearly understood. Some researchers suggest that DP is a mild and reversible form of non-arteritic anterior ischemic optic neuropathy (NA-AION) with ischemic pathophysiology.⁸ In contrast, the theory that DP is a disease entity unto itself was supported based on the distinct clinical characteristics of DP from NA-AION, such as a younger age of onset, insidious onset, lack of APDs, and lack of permanent sequelae.⁹ In addition, different FA findings of DP from NA-AION, including diffuse hyperfluorescence with hyperpermeability, support the argument that the pathophysiology of DP differs that of NA-AION.^{1,9}

However, many researchers agree that vasculopathy, which is the underlying mechanism of diabetic retinopathy and DME, can also occur in the optic nerve capillaries.¹⁰ This optic nerve capillary vasculopathy can cause disc telangiectasias and optic disc vasostatic perfusion deficiency, which may cause disc edema and toxicity to the optic disc, namely DP.^{10–12} Upregulation and pathologic changes associated with the action of several inflammatory and vasogenic mediators are responsible for the vasculopathy of diabetic retinopathy, DME, and DP.¹³ The role of inflammatory and vasogenic mediators in the pathogenesis of DP, such as increased vascular permeability, vasogenic disc edema, and disc vessel changes, can explain the effect of corticosteroids and anti-VEGF agents in resolving the edema and superficial fine telangiectatic vessels of the optic disc.¹⁴

Optic disc swelling can create artifacts that prevent an adequate assessment of the optic disc vasculature. Fard et al. showed OCTA images of the various causes of optic disc swelling.¹⁵ Visual continuity along the length of the major vessels decreased since the large vessels were obscured in papilledema. In contrast, the large vessels were clearly visualized in NA-IION and optic neuritis. In the present study, DP did not show distortion or obscuration of the large vessels, suggesting that disc swelling in DP creates fewer artifacts to hinder the assessment of the disc vasculature.

This is the first report of the evaluation of disc vessel changes of DP after intervention with SS-OCTA. OCTA offers several advantages over FA in that it is non-invasive, faster, and allows better visualization and quantitative measurements of the microvasculature. OCTA is suitable for the evaluation of disc vessel changes of DP because leakage from the telangiectatic vessels can obscure the vascular details of these pathologic vessels on FA. In addition, SS-OCTA uses a longer wavelength, offering better detection of signals from the deeper layers, such as the optic disc.¹⁶ In the present patient, the intravitreal bevacizumab injection improved BCVA, decreased disc swelling, and radially oriented telangiectatic vessels of the optic disc. Fundoscopy and SS-OCTA clearly showed evolution of disc vessel changes and resolution of venous engorgement with radially oriented disc telangiectasias.

administered an intravitreal injection of bevacizumab (1.25 mg/0.05 mL) OD. After 2 weeks, BCVA improved to 20/33 OD, but remained constant OS. The disc swelling, radially oriented telangiectatic vessels, and peripapillary splinter hemorrhages decreased OU (Fig. 3E and F).

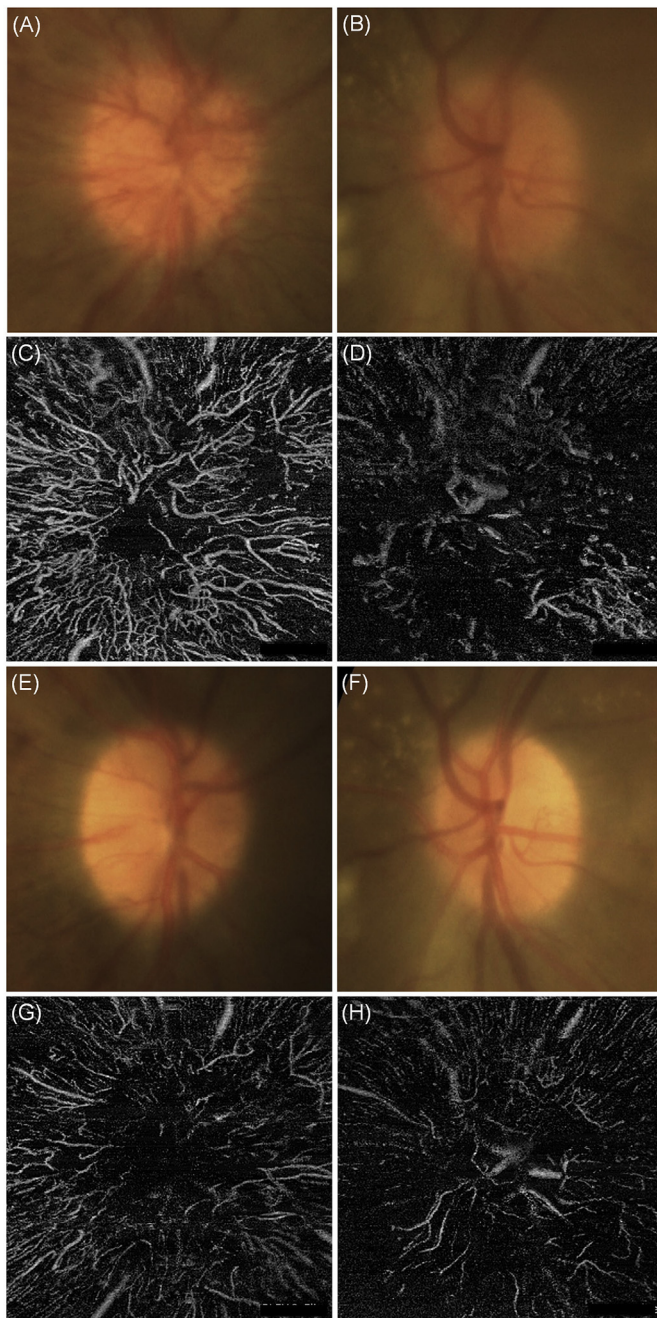


Fig. 3. Two weeks after the intravitreal bevacizumab injection in the left eye (OS), the right eye (OD) showed no interval changes (A, C). The left eye showed decreased disc swelling, radially oriented telangiectatic vessels, and peripapillary splinter hemorrhages (B) and decreased radially oriented telangiectatic vessels in the superficial retinal nerve fiber layer (RNFL) slab (D). Two weeks after the intravitreal bevacizumab injection OD (4 weeks after the injection OS), radially oriented telangiectatic vessels and peripapillary splinter hemorrhages had decreased OU (E, F). The radially oriented telangiectatic vessels in the superficial RNFL slab had also decreased OU (G, H). The first column (A, C, E, G) corresponds to the right eye and the second column (B, D, F, H) to the left.

4. Conclusion

This case showed that anti-VEGF agents (such as bevacizumab) are a useful treatment option for DP as they resolve underlying optic nerve

capillary vasculopathy. SS-OCTA clearly depicted resolved superficial telangiectatic vessels of the optic disc. However, further research including larger samples is warranted to confirm our findings.

4.1. Patient consent

Written consent to publish case details was obtained from the patient.

Funding

This work was supported by the National Research Foundation of Korea (NRF) grant funded by the Korea government (MSIT) (No. 2019R1G1A1098872).

Authorship

All authors attest that they meet the current ICMJE criteria for Authorship.

Declaration of competing interest

All authors have no financial disclosures.

Acknowledgements

None.

Appendix A. Supplementary data

Supplementary data to this article can be found online at <https://doi.org/10.1016/j.ajoc.2020.100748>.

References

- Regillo CD, Brown GC, Savino PJ, et al. Diabetic papillopathy. Patient characteristics and fundus findings. *Arch Ophthalmol*. 1995;113(7):889–895.
- Giuliani GP, Sadaka A, Chang PY, Cortez RT. Diabetic papillopathy: current and new treatment options. *Curr Diabetes Rev*. 2011;7(3):171–175.
- Willerslev A, Munch IC, Larsen M. Resolution of diabetic papillopathy after a single intravitreal injection of ranibizumab. *Acta Ophthalmol*. 2012;90(5):e407–e409.
- Kim M, Lee JH, Lee SJ. Diabetic papillopathy with macular edema treated with intravitreal ranibizumab. *Clin Ophthalmol*. 2013;7:2257–2260.
- Chin EK, Almeida DR, Sohn EH. Sustained and expedited resolution of diabetic papillopathy with combined PRP and bevacizumab. *Can J Ophthalmol*. 2015;50(5):e88–91.
- Yildirim M, Kilic D, Dursun ME, Dursun B. Diabetic papillopathy treated with intravitreal ranibizumab. *Int Med Case Rep J*. 2017;10:99–103.
- de Ungria JM, Del Priore LV, Hart W. Abnormal disc vessels after diabetic papillopathy. *Arch Ophthalmol*. 1995;113(2):245–246.
- Hayreh SS, Zimmerman MB. Nonarteritic anterior ischemic optic neuropathy: clinical characteristics in diabetic patients versus nondiabetic patients. *Ophthalmology*. 2008;115(10):1818–1825.
- Bayraktar Z, Alacali N, Bayraktar S. Diabetic papillopathy in type II diabetic patients. *Retina*. 2002;22(6):752–758.
- Slagle WS, Musick AN, Eckermann DR. Diabetic papillopathy and its relation to optic nerve ischemia. *Optom Vis Sci*. 2009;86(4):e395–403.
- Freund M, Carmon A, Cohen AM. Papilledema and papillitis IN diabetes: report OF two cases. *Am J Ophthalmol*. 1965;60:18–20.
- Yanko L, Ticho U, Ivry M. Optic nerve involvement in diabetes. *Acta Ophthalmol*. 1972;50:556–564.
- Miller K, Fortun JA. Diabetic macular edema: current understanding, pharmacologic treatment options, and developing therapies. *Asia Pac J Ophthalmol*. 2018;7(1):28–35.
- Weis SM, Cheresch DA. Pathophysiological consequences of VEGF-induced vascular permeability. *Nature*. 2005;437(7058):497–504.
- Fard MA, Jalili J, Sahraian A, et al. Optical coherence tomography angiography in optic disc swelling. *Am J Ophthalmol*. 2018;191:116–123.
- Lavinsky F, Lavinsky D. Novel perspectives on swept-source optical coherence tomography. *Int J Retina Vitreous*. 2016;2:25.